



Non-Glaucomatous Visual Field Defects

María Isabel Canut Jordana
Gema Rebolleda Fernández
Andrés Fernández-Vega Cueto-Felgueroso
Marta Mármol Díaz

Non-Glaucomatous Visual Field Defects

Editorial Glosa, S.L.

Avinguda de la Meridiana 358, 10th floor - 08027 Barcelona (Spain)

Tel. no.: 932 684 946 – email: informacion@editorialglosa.es

www.editorialglosa.es



ISBN: 978-84-7429-764-5

© María Isabel Canut Jordana and Gema Rebolleda Fernández

© Editorial Glosa S.L.

All rights reserved. No part of this publication may be reproduced or transmitted in any way or in any format, including photocopies or any information retrieval system, without the written authorisation of the holder of the rights.

Authors



María Isabel Canut Jordana

Chief Coordinator of the Glaucoma Department.
Barraquer Ophthalmology Center Barcelona (Spain).



Gema Rebolleda Fernández

Head of the Glaucoma and Neuro-Ophthalmology Division.
Ramón y Cajal University Hospital. Madrid (Spain).
Professor of Ophthalmology. University of Alcalá.
Alcalá de Henares (Madrid, Spain).



Andrés Fernández-Vega Cueto-Felgueroso

Assistant Ophthalmologist. Department of Glaucoma.
Fernández-Vega Ophthalmological Institute. Oviedo (Asturias, Spain).



Marta Mármol Díaz

Assistant Ophthalmologist. Department of Glaucoma.
Barraquer Ophthalmology Center Barcelona (Spain).



Marco Sales Sanz

Assistant Doctor. Orbit and Oculoplastics Department.
Ophthalmology Department. Ramón y Cajal Hospital. Madrid (Spain).
Oculoplastics Unit. Novovisión. Madrid (Spain).

Table of Contents

Introduction.....	9
Congenital Disc Alterations	
1. Optic Disc Drusen.....	11
2. Tilted Disc.....	25
3. Optic Nerve Hypoplasia.....	39
4. Optic Disc Coloboma.....	49
5. Congenital Optic Disc Pit.....	59
6. Morning Glory Disc Anomaly.....	71
7. High Myopia.....	79
Acquired Neurological Defects	
8. Acquired Neurological Defects: Vascular.....	89
9. Acquired Neurological Defects: Compressive.....	103
10. Acquired Neurological Defects: Toxic and Metabolic.....	123

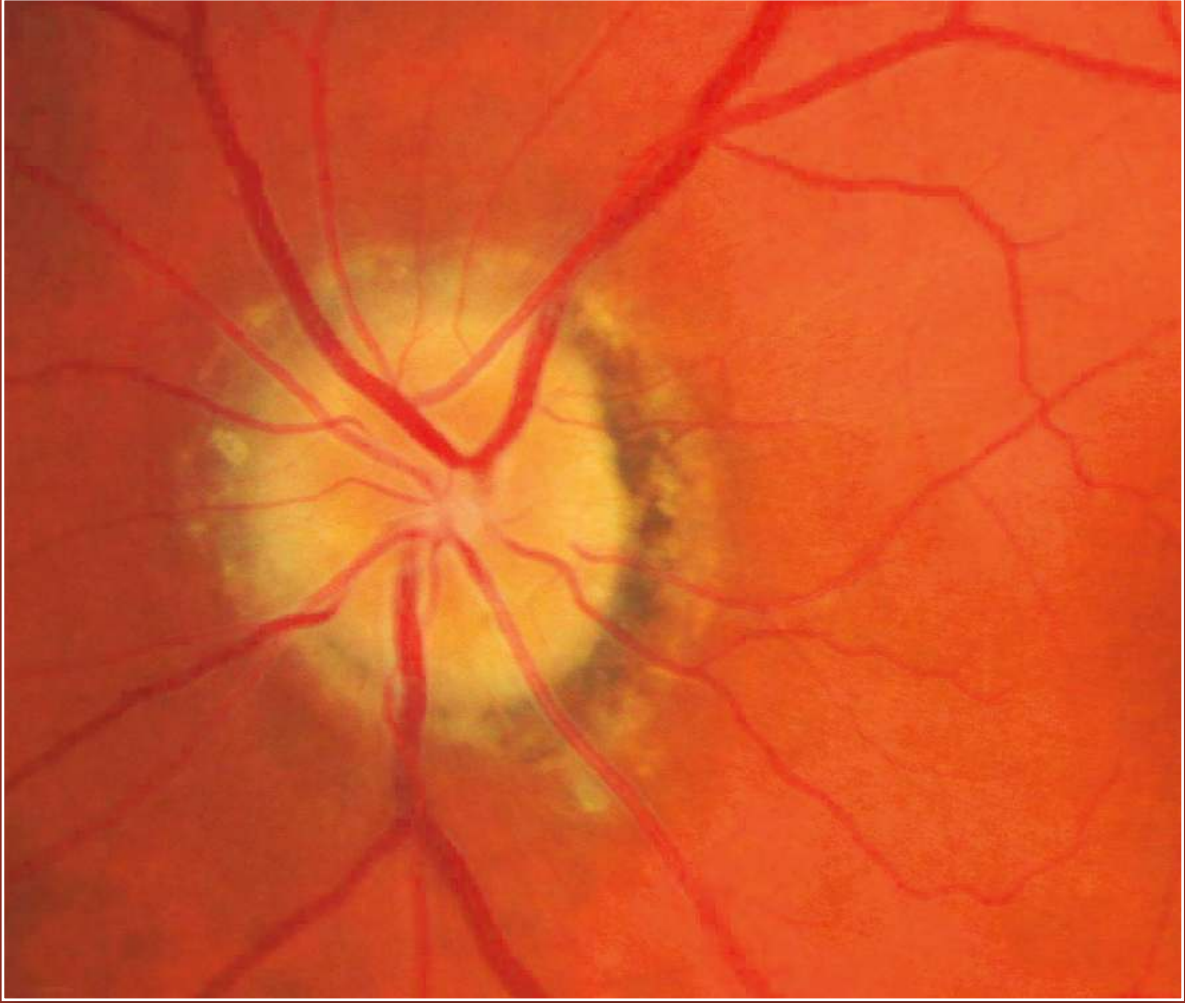
Introduction

Imaging testing has provided an extremely helpful diagnostic tool, particularly for the purpose of confirming diagnostic impressions in any field of medicine. In relation to glaucoma disease, tests such as campimetry should no longer be thought of as complementary, as they are an inseparable part of the diagnosis and monitoring of the evolution of any patient with suspected glaucoma. The same has happened in this last decade with optical coherence tomography (OCT), another tool that has become absolutely necessary for doctors to confirm their suspicions or trigger justified doubts in the sometimes-difficult process of making a diagnosis. The huge amount of information provided by these tests, as well as doctors' dependence on them, which we readily admit to, may lead to an ease of interpretation from which there is no way back, preventing us from seeing anything more than a shadow of glaucoma in the event of any faults in these tests.

Faced with the undoubtedly mistaken assumption of a binominal distribution under which visual fields are exclusive to glaucoma, our aim is to question this premise and provide accounts of cases of visual field defects and OCT results with no direct link to glaucomatous disease. In order to do this, we have selected the ten most relevant defects in terms of prevalence and ease of confusion, with their resulting possible therapeutic implications.

We could probably have drawn up a longer list, but this guidebook is enough to achieve our purpose of encouraging reflection in this area, and we can assert with certainty that these two tests – which by the end of this decade should stop being thought of as complementary or associated with glaucoma diagnoses – will become even more helpful in the differential diagnosis of all diseases of the optic nerve and the retinal nerve fibre layer.

María Isabel Canut Jordana, MD PhD



Optic Disc Drusen

Gema Rebolleda Fernández
Andrés Fernández-Vega Cueto-Felgueroso
María Isabel Canut Jordana

1

A

Definition

Optic nerve drusen are globular masses made up of a matrix of mucopolysaccharides, nucleic acids, amino acids and varying amounts of calcium. They are dynamic structures whose appearance, size and location all change with age, evolving from being deep drusen with no or almost no calcium and buried during childhood to more superficial, visible and calcified drusen in adults (Fig. 1).

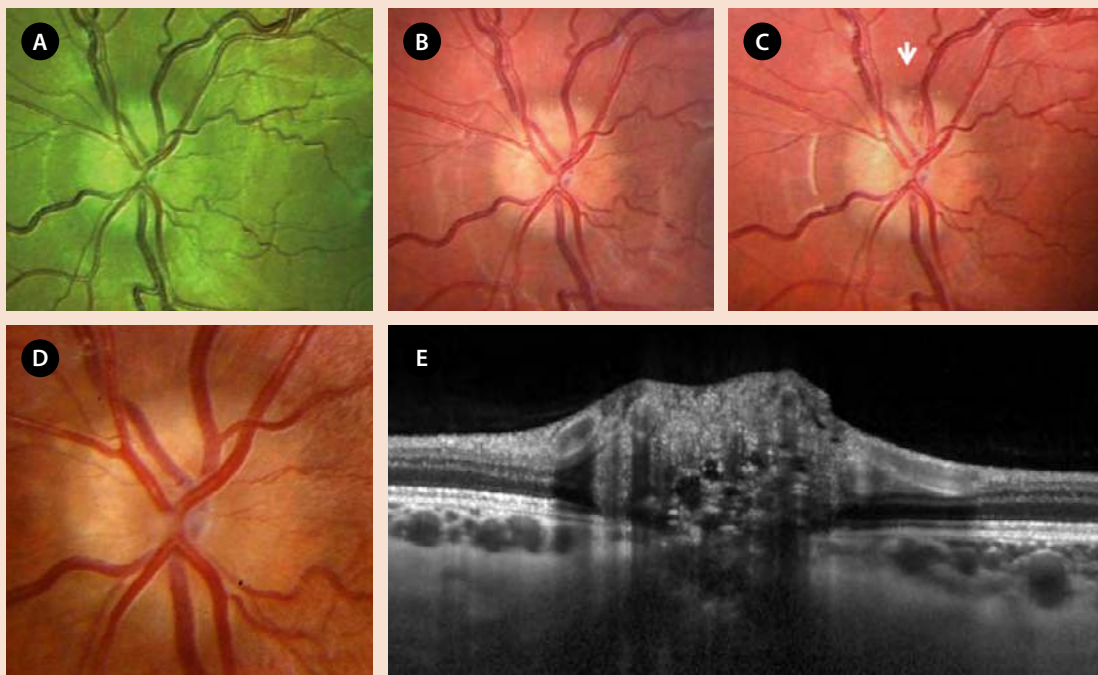


Figure 1. Optic nerve drusen are dynamic structures that usually become more superficial over time. **A:** Retinography with red-free light where the course of the vessels can be observed and the presence of disc oedema can be ruled out. **B:** Disc pseudo-oedema caused by buried drusen in a 10-year-old girl. **C:** Epipapillary haemorrhage at the time of diagnosis, which resolves in a month. **D:** Visible drusen in the same patient six years later. **E:** Typical appearance with enhanced depth imaging optical coherence tomography (EDI-OCT), as hyporeflective structures with a hyperreflective margin.

B

Etiopathogenesis and Prevalence

Although their pathogenesis is disputed, the classical theory points to a congenital narrow scleral canal resulting in compression or hindrance of axonal transport. They are more common in women and run in families, and they are rarer in people of African or Asian descent. Their prevalence varies between 0.4% seen in daily clinical practice and 14.6% according to recent optical coherence tomography (OCT) criteria. The frequency of bilateral cases similarly varies from 75% clinically to 95% according to OCT.

C

Classification

1. **Buried/hidden drusen:** These usually appear in early childhood and are hard to detect clinically due to their deeper position. Furthermore, they are usually smaller and with a lower calcium content in young children (Fig. 1).
2. **Visible drusen:** These can be easily detected due to their characteristic globe-shaped appearance with pearly irregularities (Figs. 2-5).

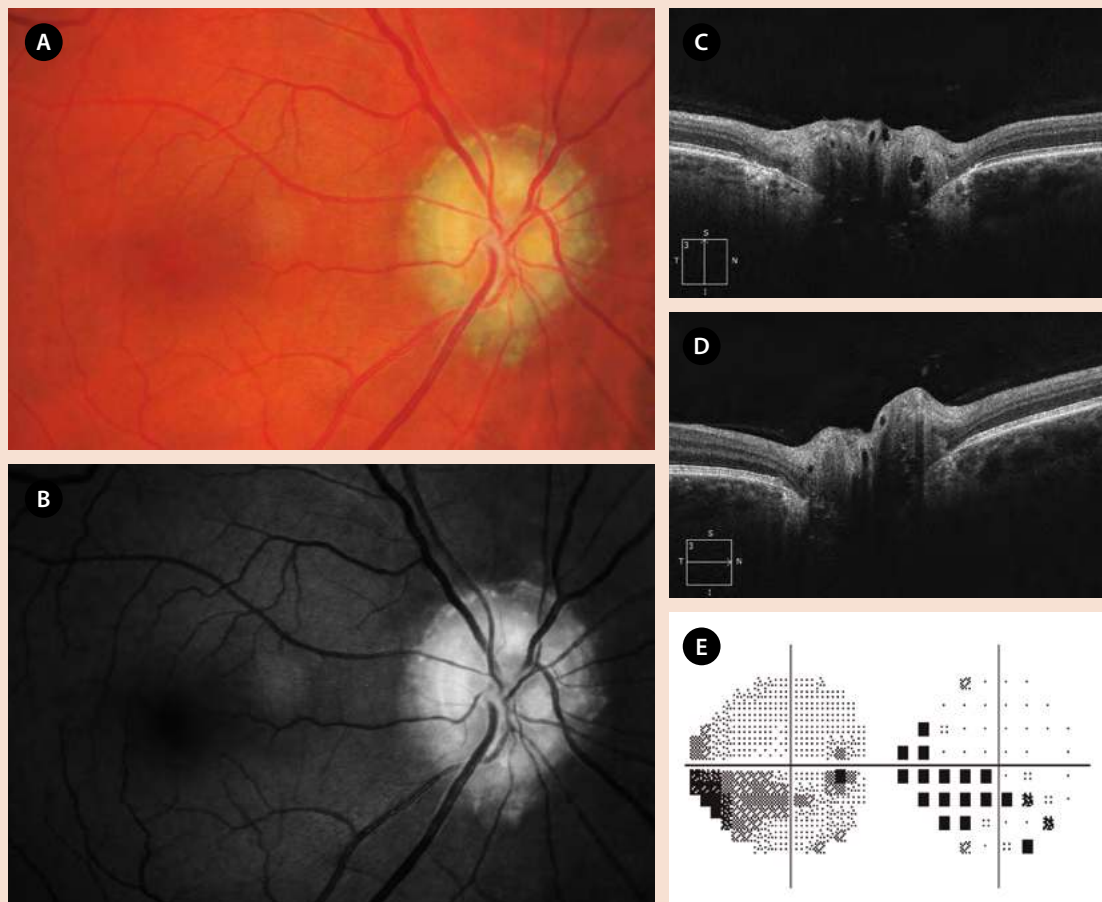


Figure 2. **A:** Visible drusen in the right optic nerve. **A:** An optic disc with no excavation and an irregular pearly appearance, with scalloped rims and visible drusen on the surface. **B:** Red-free light clearly showing the course of blood vessels. **C and D:** Vertical and horizontal cross-sections of CIRRUS™ HD-OCT-5000 optical coherence tomography images showing a characteristic ovoid hyporeflective cavity with a partial hyperreflective border, next to a peripapillary hyperreflective ovoid mass-like structure (PHOMS)(C). **E:** Predominantly inferior arciform defect.

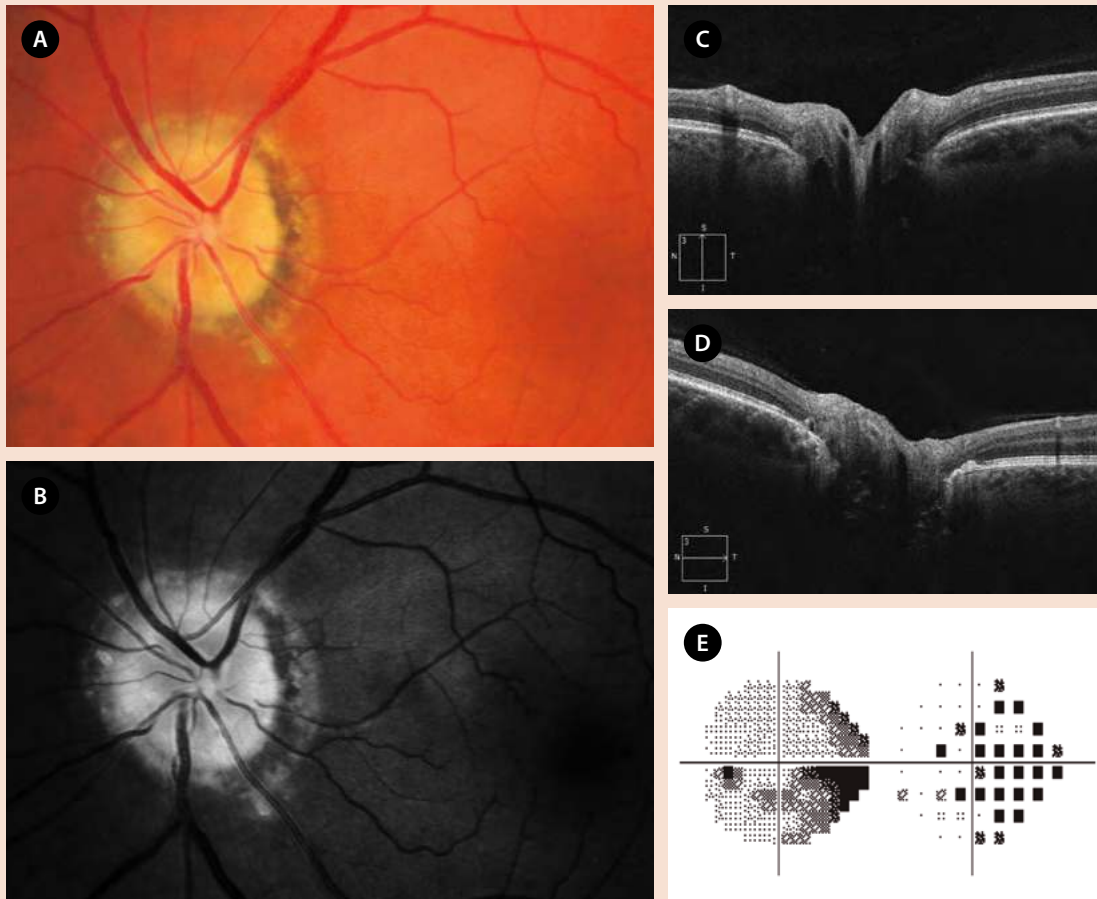


Figure 3. Visible drusen in the same patient's left optic nerve, with the same morphological characteristics in a retinography (A) and with red-free light (B). C and D: Vertical and horizontal cross-sections of CIRRUS™ HD-OCT-5000 optical coherence tomography images with a predominance of hyperreflective bands. E: Predominantly inferior double-arched moderate visual field defect.

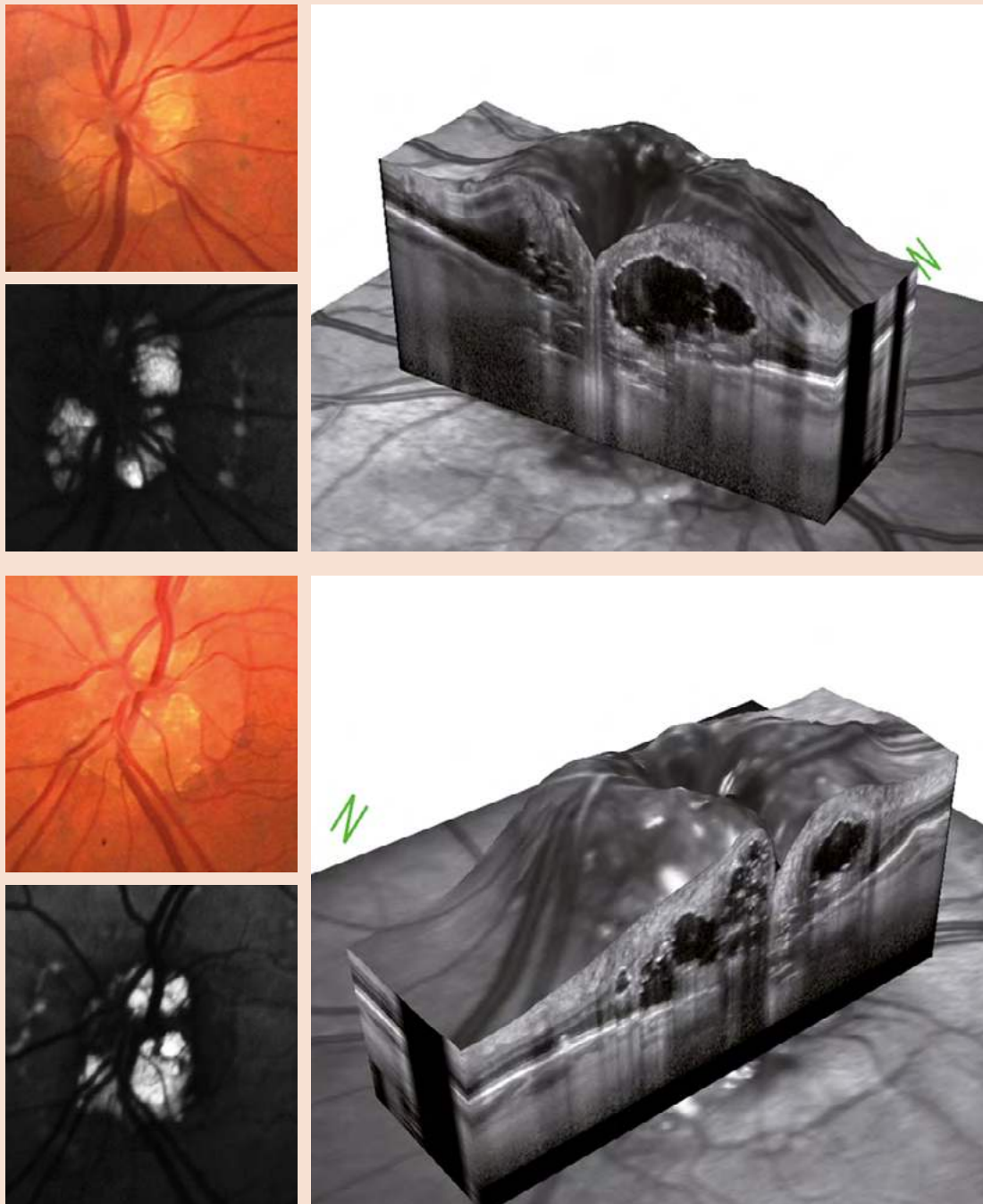


Figure 4. Optic nerve drusen can appear more commonly in some systemic diseases, such as familial calcinosis, with large numbers of drusen in both eyes (**right eye: upper image; left eye: lower image**), as well as with various patterns on enhanced depth imaging optical coherence tomography (EDI-OCT), depending on location and composition.

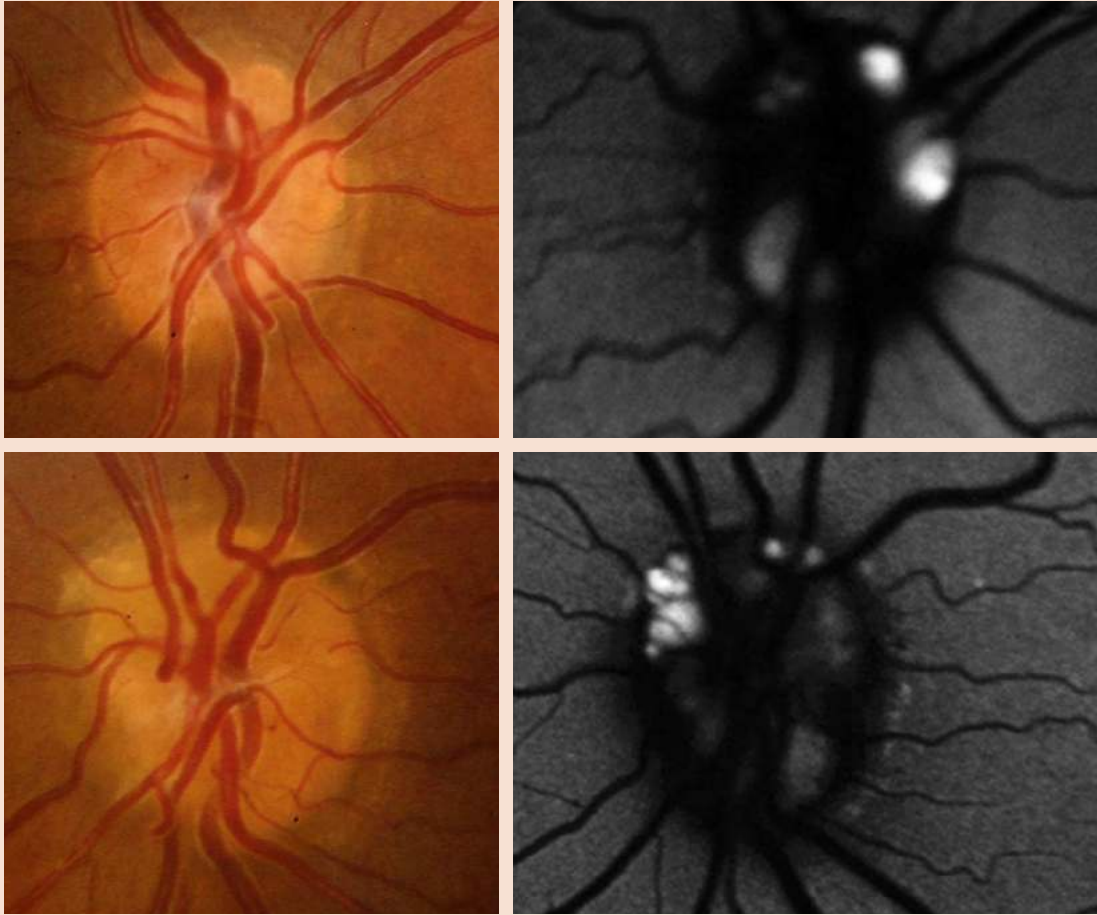


Figure 5. Although autofluorescence is typical of visible drusen, as in these two cases, diagnostic sensitivity is significantly reduced in the case of buried drusen.

D

Clinical Signs

Buried drusen:

- Waxy raised optic disc with scalloped rims and no excavations. What makes it clinically different from papillary oedema is that the course of superficial vessels is not hidden (Fig. 1).
- Abnormal vascular patterns (early branching, trifurcations, prepapillary loops, vascular tortuosity, or cilioretinal arteries) are common (Fig. 1).
- Although rare, epipapillary haemorrhages (Fig. 1), isolated subretinal haemorrhages (Fig. 6) or haemorrhages associated with peripapillary neovascularisation can sometimes be observed.

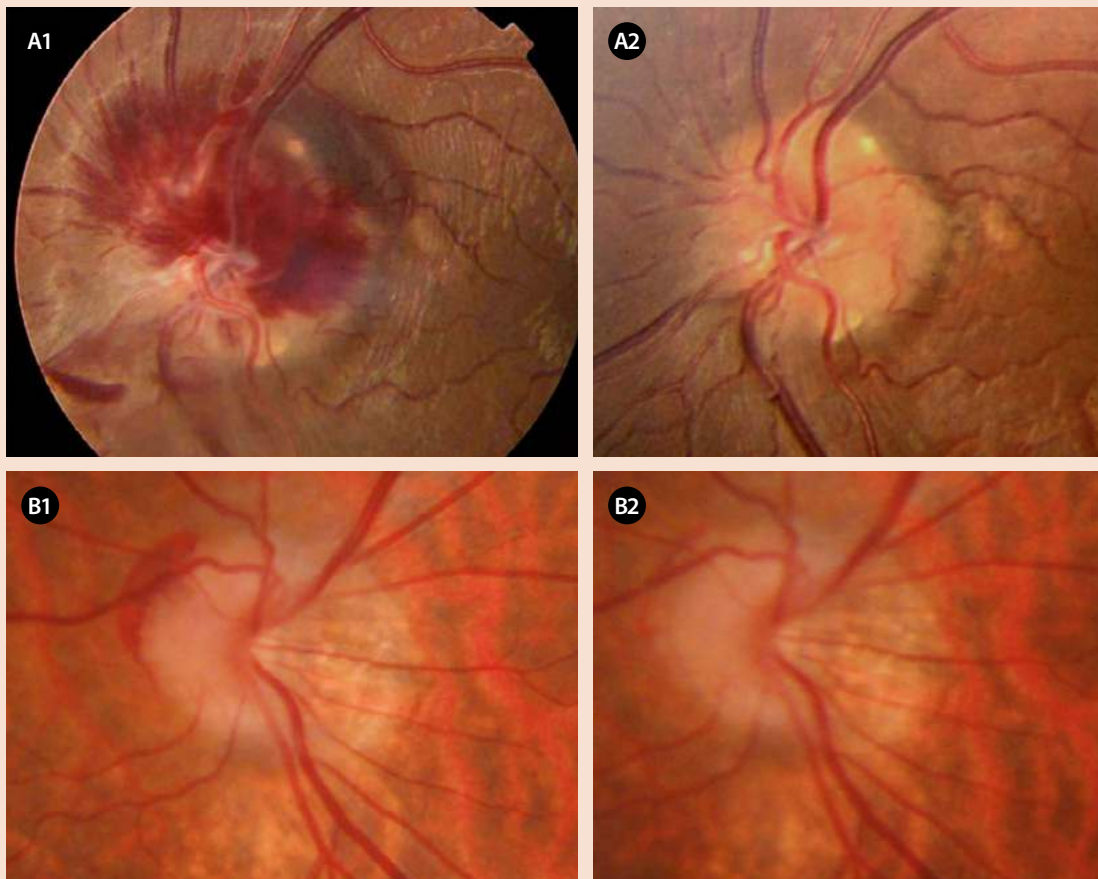
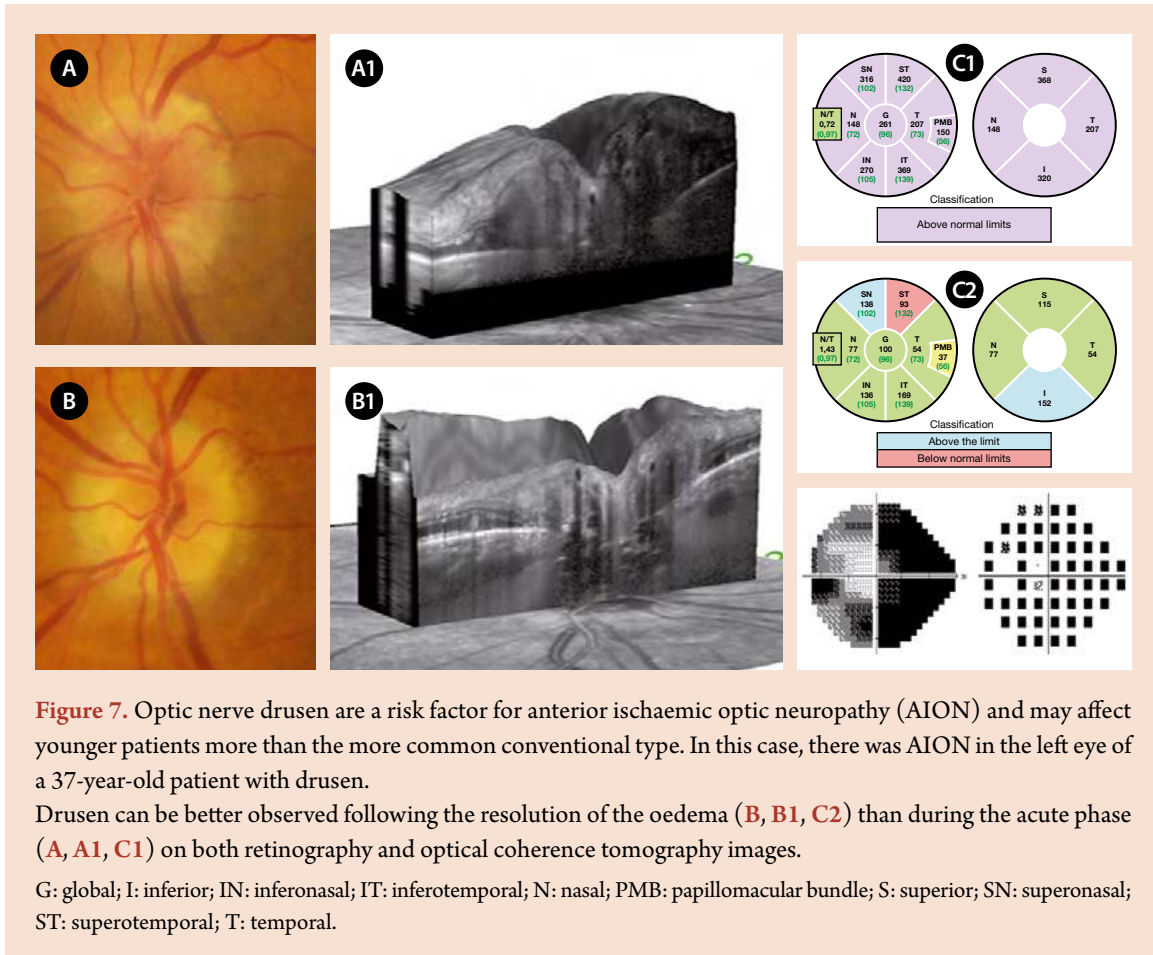


Figure 6. Optic nerve drusen can be associated with haemorrhages, usually peripapillary haemorrhages (A1, B1). These can compromise the diagnosis and make it necessary to rule out a neovascular membrane. In both the above cases (A2, B2), they were isolated and resolved spontaneously.

- Drusen can result in a predisposition to anterior ischaemic optic neuropathy (AION), which is characterised by affecting younger patients and with a better visual prognosis than classic AION (Fig. 7). They may also be associated with vascular compromise involving an obstructed central retinal artery or vein.



- In the typical clinical course, gradual visual field loss is associated with retained central visual acuity.
- Visual field defects are more common in patients with large, confluent and autofluorescent drusen.
- The most sensitive diagnostic tests currently available are EDI-OCT (enhanced depth imaging optical coherence tomography) and swept-source optical coherence tomography (SS-OCT). The diagnostic sensitivity of B-mode ultrasound and autofluorescence is limited in the case of hidden drusen in children (small, low calcium content, and deeper).
- Three morphological patterns have been described using OCT imaging and can be found together in the same eye (Fig. 8):
 - Ovoid hyporeflective structures with a hyperreflective margin (Fig. 4)
 - Peripapillary hyperreflective ovoid mass-like structure (PHOMS) (Fig. 2C)
 - Hyperreflective bands (Fig. 3).

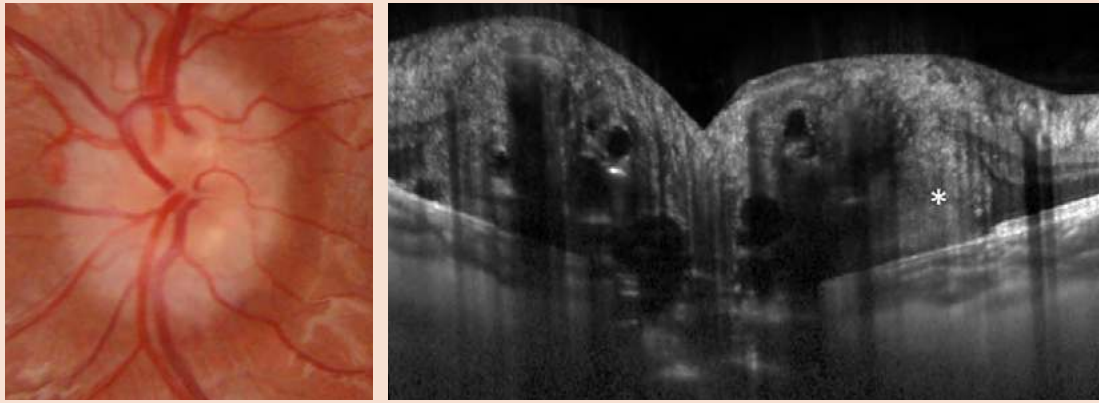


Figure 8. Enhanced depth imaging optical coherence tomography (EDI-OCT) makes it possible to see all three patterns simultaneously, as in this case: peripapillary hyperreflective ovoid mass-like structure PHOMS(*), multiple round or ovoid hyporeflective cavities, which is the only pattern recommended by the ODDS Consortium for making a drusen diagnosis, and hyperreflective linear bands.

The Optic Disc Drusen Studies (ODDS) Consortium just defined optic disc drusen as hyporeflective structures with a full or partial hyperreflective margin. By contrast, PHOMS are seen in many conditions, including papilledema, non-arteritic anterior ischemic optic neuropathy, central retinal vein occlusion, optic disc drusen, and tilted discs. They are a common but non-specific OCT marker of axoplasmic stasis in the optic nerve head.

Although hyperreflective horizontal bands may be a sign of nascent drusen, the ODDS Consortium does not recommend diagnosing this as drusen until further evidence is available.

E

Differential Diagnosis

- In cases of bilateral drusen: optic disc oedema (intracranial hypertension).
- In cases of unilateral drusen: entities that cause oedema or blurring of the disc (papillitis, anterior ischaemic optic neuropathy, tilted disc, etc.).
- Optic atrophy.



Systemic Associations

- Alagille syndrome.
- Pseudoxanthoma elasticum.
- Retinitis pigmentosa.
- Familial calcinosis (Fig. 4).
- Angioid streaks.

G

Key Points

1

Drusen are mostly asymptomatic and diagnosed as part of routine examinations or examinations carried out due to intercurrent headaches.

2

They are the most common cause of “pseudopapilloedema”, and the differential diagnosis with true optic disc oedema (intracranial hypertension) is key in order to avoid exhaustive diagnostic protocols and unnecessary invasive tests.

3

In the event of doubt when making a diagnosis, apart from the clinical aspect and an examination of the patient’s relatives, the new OCT technologies (EDI and SS) are the tests of choice, as they provide more diagnostic sensitivity than ultrasound and autofluorescence (Fig. 5). This is because they make it possible to see not only the morphological characteristics of drusen (area, volume, location and composition) but also how they relate to the structures around them (Figs. 1-4, 7 and 8).

- Drusen are characterised by hyporeflective ovoid structures with a signal-poor core and often with a hyperreflective margin.
- Peripapillary hyperreflective ovoid mass-like structures (PHOMS) can be seen in association with optic disc drusen and a wide spectrum of other conditions, and should
- Hyperreflective lines may represent early drusen but should not be diagnosed as drusen.

4

OCT examinations of ganglion cells at macular level are more sensitive than peripapillary examinations of the nerve fibre layer for the detection of any associated neuronal damage.

5

If a patient with optic nerve drusen reports a sudden loss of vision, all other possible diagnoses must be ruled out.

6

The association of drusen and glaucoma in the same patient makes it difficult to establish which of the two is responsible for any progression of neuropathy.

7

We must stress that patients with drusen may develop intracranial hypertension or other neuropathies, combining features of several diseases (Fig. 7).



Bibliography

Auw-Haedrich C, Staubach F, Witschel H. Optic disk drusen. *Surv Ophthalmol.* 2002;47(6):515-32.

Casado A, Rebolleda G, Guerrero L, Leal M, Contreras I, Oblanca N, et al. Measurement of retinal nerve fiber layer and macular ganglion cell-inner plexiform layer with spectral-domain optical coherence tomography in patients with optic nerve head drusen. *Graefes Arch Clin Exp Ophthalmol.* 2014;252(10):1653-60.

Chang MY, Pineles SL. Optic disk drusen in children. *Surv Ophthalmol.* 2016;61(6):745-58.

Fraser JA, Sibony PA, Petzold A, Thaug C, Hamann S; ODDS Consortium. Peripapillary Hyper-reflective Ovoid Mass-like Structure (PHOMS): An Optical Coherence Tomography Marker of Axoplasmic Stasis in the Optic Nerve Head. *J Neuroophthalmol.* 2021 Dec 1;41(4):431-41.

Ghassibi MP, Chien JL, Abumasmah RK, Liebmann JM, Ritch R, Park SC. Optic nerve head drusen prevalence and associated factors in clinically normal subjects measured using optical coherence tomography. *Ophthalmology.* 2017;124(3):320-5.

Lee KM, Woo SJ, Hwang JM. Morphologic characteristics of optic nerve head drusen on spectral-domain optical coherence tomography. *Am J Ophthalmol.* 2013;155(6):1139-47.

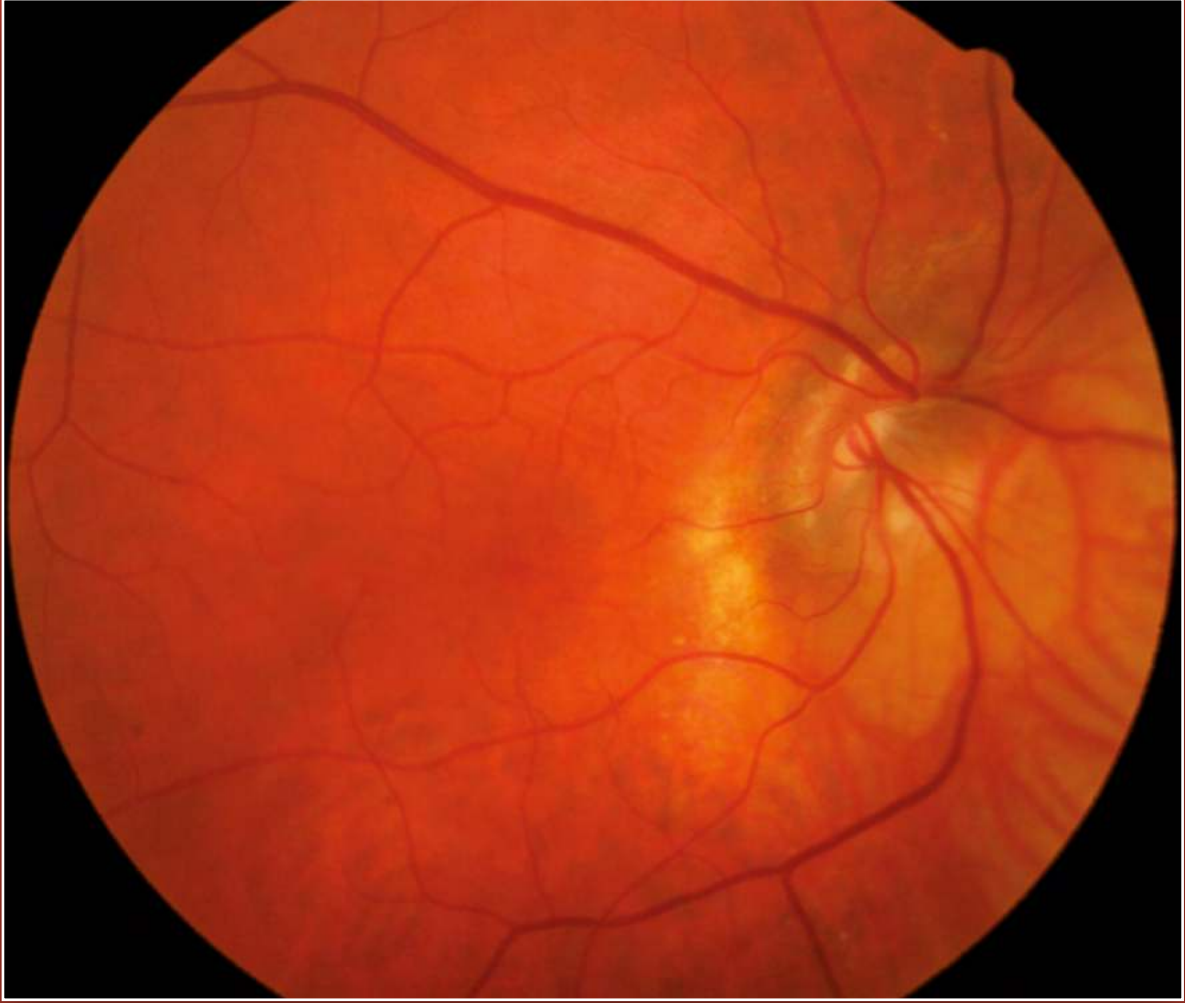
Malmqvist L, Lindberg AW, Dahl VA, Jørgensen TM, Hamann S. Quantitatively measured anatomic location and volume of optic disc drusen: an enhanced depth imaging optical coherence tomography study. *Invest Ophthalmol Vis Sci.* 2017;58(5):2491-7.

Malmqvist L, Bursztyn L, Costello F, Digre K, Fraser JA, Fraser C et al. The Optic Disc Drusen Studies Consortium Recommendations for Diagnosis of Optic Disc Drusen Using Optical Coherence Tomography. *J Neuroophthalmol* 2018;38(3):299-307.

Rebolleda G, Díez-Álvarez L, Casado A, Sánchez-Sánchez C, De Dompablo E, González-López JJ, et al. OCT: new perspectives in neuro-ophthalmology. *Saudi J Ophthalmol.* 2015;29(1):9-25.

Rebolleda G, Kawasaki A, De Juan V, Oblanca N, Muñoz-Negrete FJ. Optical coherence tomography to differentiate papilledema from pseudopapilledema. *Curr Neurol Neurosci Rep.* 2017;17(10):74.

Traber GL, Weber KP, Sabah M, Keane PA, Plant GT. Enhanced depth imaging optical coherence tomography of optic nerve head drusen: a comparison of cases with and without visual field loss. *Ophthalmology.* 2017;124(1):66-73.



Tilted Disc

**Gema Rebolleda Fernández
Andrés Fernández-Vega Cueto-Felgueroso
María Isabel Canut Jordana**

2

A

Definition

Tilted or oblique disc, also known as *Fuchs' coloboma*, *congenital crescent*, *coloboma of the disc* or *dysverted disc*, has two geometric features:

1. The tilted angle at which the optic nerve enters the eyeball, indirectly measured by the index of tilt (the ratio of minimum to maximum disc diameter), which is considered pathological if it is under 0.7-0.8.
2. The degree of rotation around the sagittal axis of the eyeball, or torsion, is considered pathological if it is greater than 15° , and it is present in almost 90% of cases (Fig. 1).

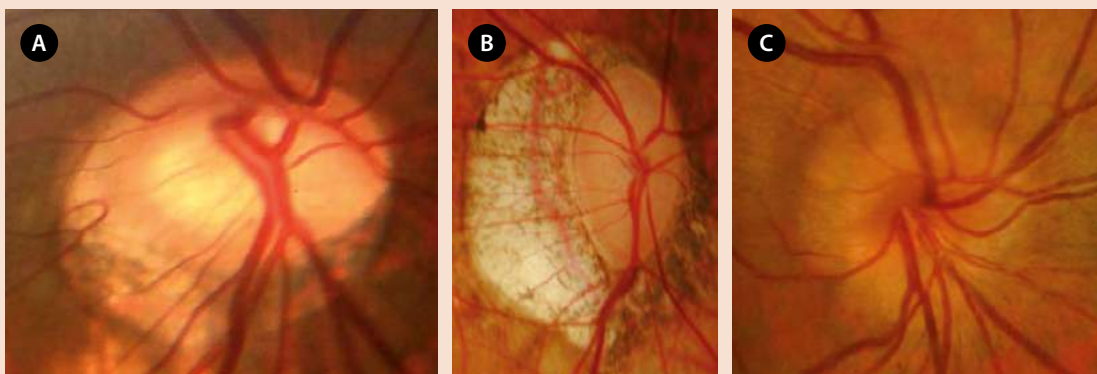


Figure 1. Horizontally tilted disc (A), 6-12 h vertical tilt without torsion (B) and tilted (C). There is a peripapillary atrophy ring (annular crescent) in all cases.

From an ophthalmoscopic point of view, the disc is excessively oval in shape, or D-shaped, with one hemisphere higher than the other. When it is bilateral (38-80%), it usually follows a mirror pattern (Fig. 2).

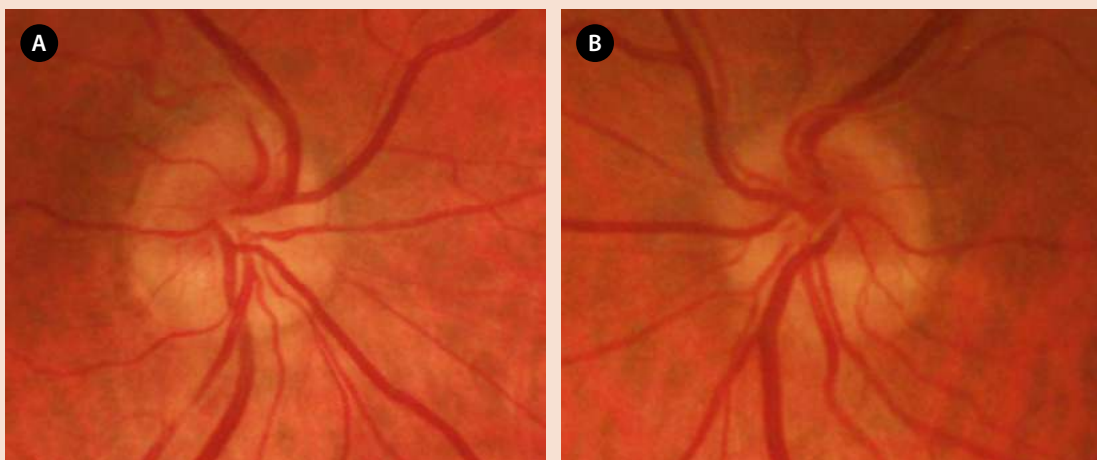


Figure 2. Bilateral tilted disc, with clockwise rotation in the right eye and anticlockwise in the left, at an approximate angle of 60° , resulting in a typical mirror image.

B

Etiopathogenesis and Prevalence

The prevalence of tilted disc varies between 0.4% and 3.5% depending on the phenotypic variant, the range of myopia included and the definition criteria. Despite being traditionally attributed to a fault in the embryonic cleft closure, its pathogenesis is unclear, and cases of acquired tilted disc have been described, with the temporal portion becoming depressed, the disc becoming oval in shape and the vessels changing course (Fig. 3).

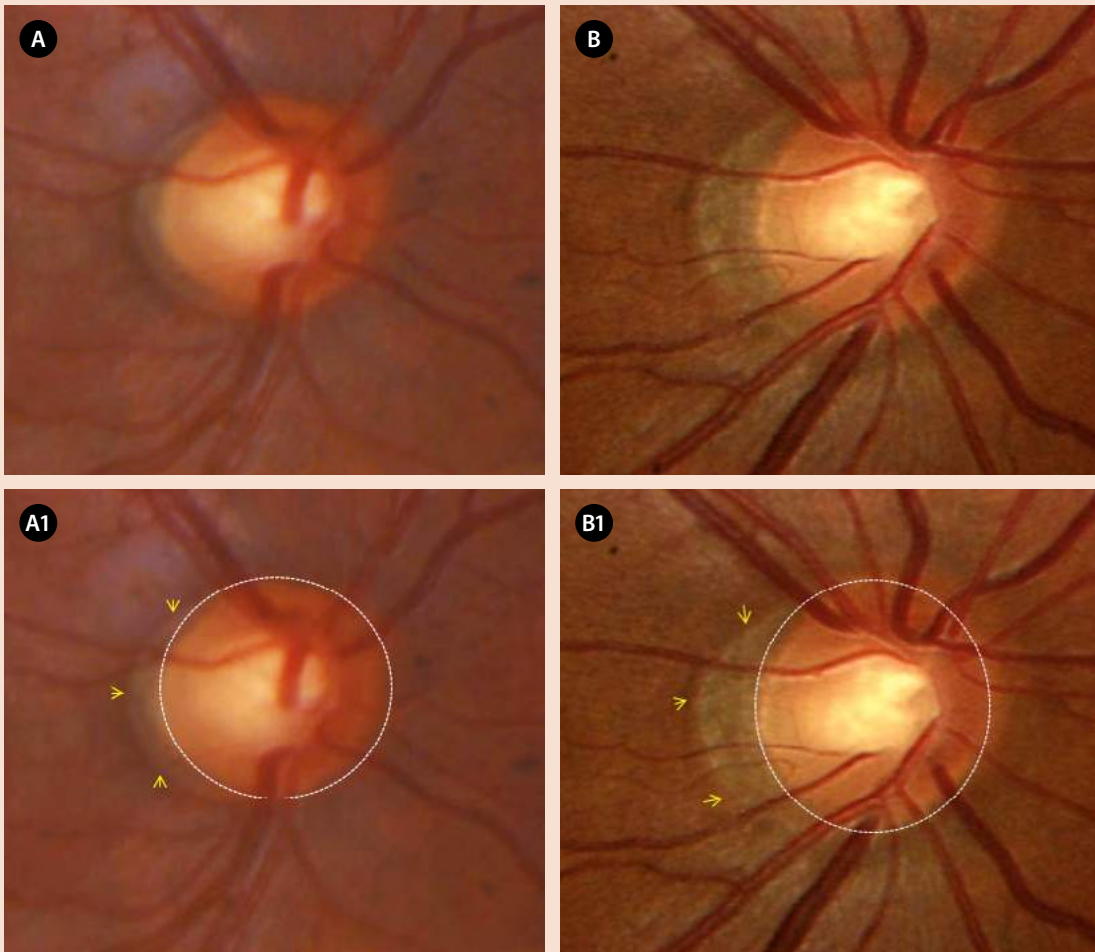


Figure 3. Gradual ovalisation of the optic disc between 2008 (A, A1) and 2013 (B, B1), with a change in course of the vessels and an increase in peripapillary atrophy (yellow arrows).

C

Classification

1. Tilted optic disc not associated with other ocular or systemic disorders.
2. Tilted disc syndrome (TDS): A combination of inferonasal tilting of the optic disc and retinal vascular and juxtapapillary changes, such as inferonasal crescent (conus), thinning or atrophy of the choroid and retinal pigment epithelium, posterior staphyloma of the affected area and situs inversus (a vascular anomaly in which the retinal vessels exit nasally before going in a temporal direction). Not all these traits are required in order to make a diagnosis. The angle between the vertical and the main axis of the disc (α) is the torsion angle (Fig. 4).

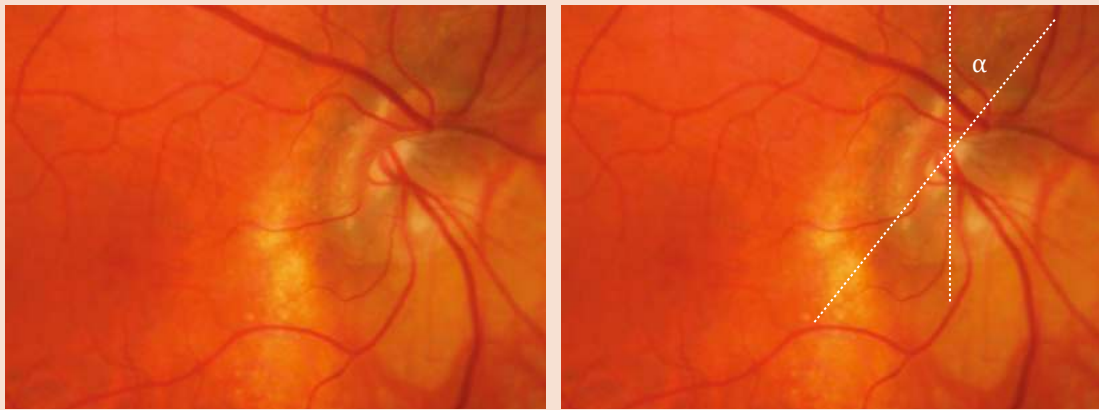


Figure 4. Tilted disc syndrome (TDS). Tilted disc rotated at an angle of 40° (α) with an inverted D shape. It is associated with myopia, astigmatism, myopic conus and posterior inferonasal staphyloma, as well as with situs inversus.

D

Clinical Signs

- Tilted disc is diagnosed clinically, focusing on the appearance of the disc (oval or D-shaped), with an axial tilt that usually goes in an inferonasal direction and a superotemporal protrusion, which can be mistaken for disc oedema (pseudo-oedema). Some associated findings include peripapillary atrophy, posterior staphyloma and the chorioretinal changes mentioned above (Figs. 5 and 6).

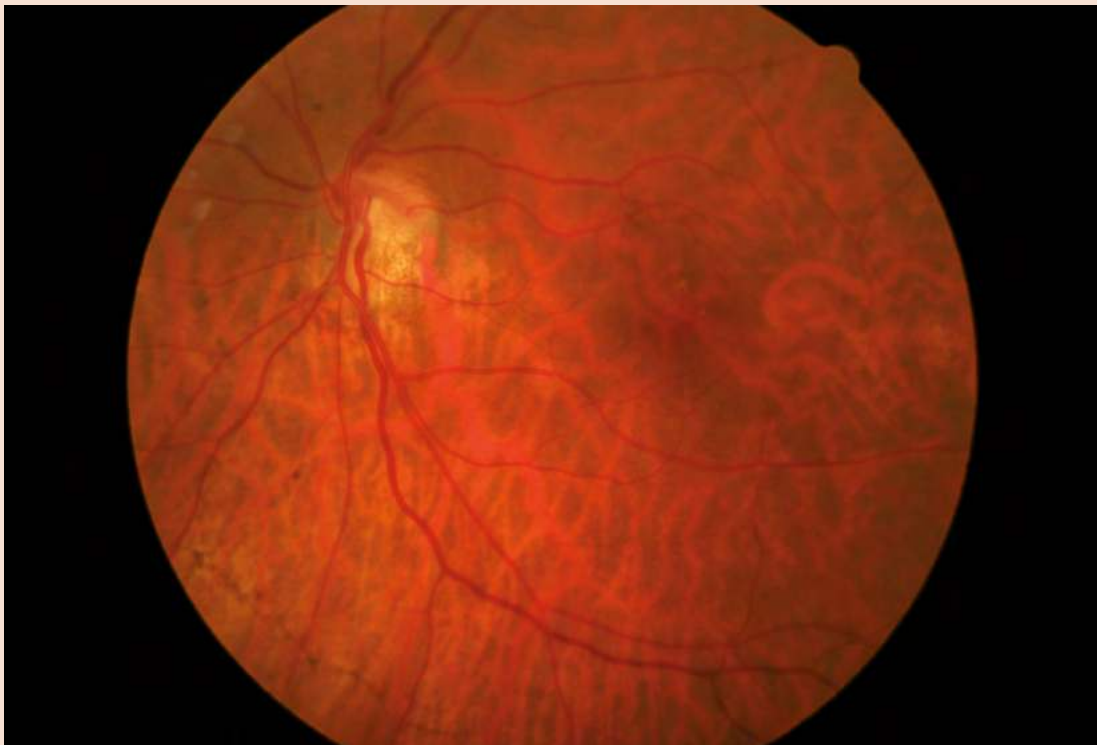


Figure 5. Tilted disc syndrome (TDS), with an almost horizontal oval-shaped disc, inferior conus and superotemporal pseudo-oedema.

- There is a link between tilted disc and myopia and astigmatism (Fig. 6).
- Visual acuity and colour vision in tilted disc cases may be slightly reduced compared to normal optic discs, with the possibility of amblyopia in unilateral cases.
- Thanks to new high-penetration optical coherence tomography (OCT) technology, it is now possible to see and outline the exact anatomy of the disc rim (the termination of Bruch's membrane (BM) and the sclera), document the degree and type of associated peripapillary atrophy, identify the tissues responsible for the clinical protrusion, measure the torsion angle, and detect any associated lamina cribrosa and peripapillary abnormalities (retinoschisis and choroidal cavitation) that are missed in ophthalmoscopic examinations (Figs. 7-9).

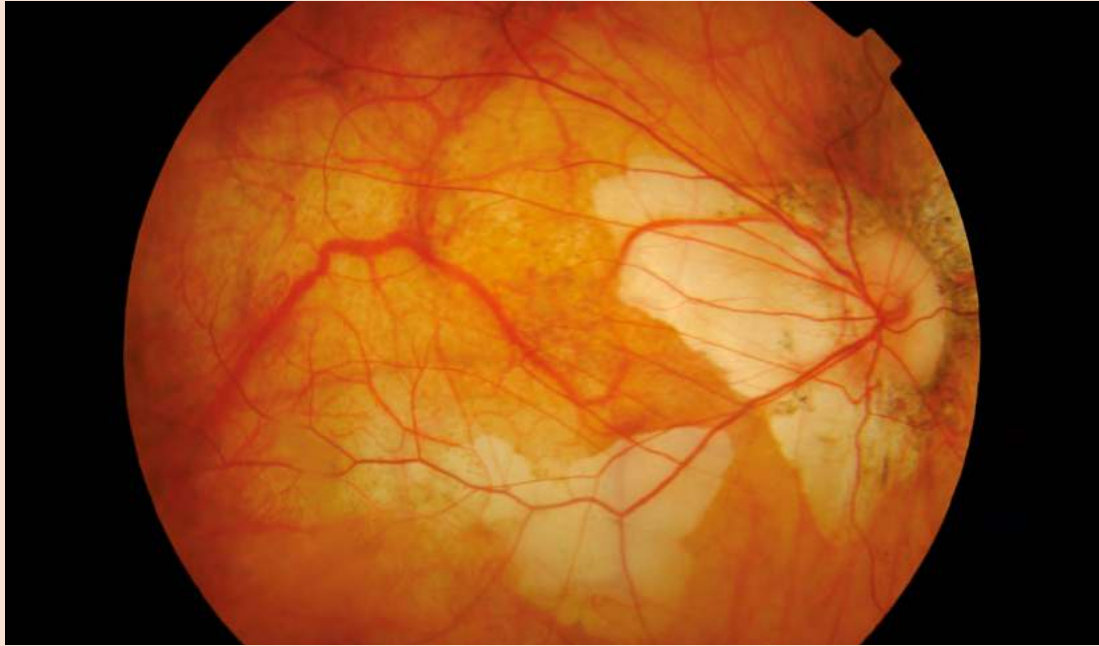


Figure 6. Tilted disc syndrome (TDS), with oval disc and temporal chorioretinal atrophy in a person with high myopia (> 6 dioptres).

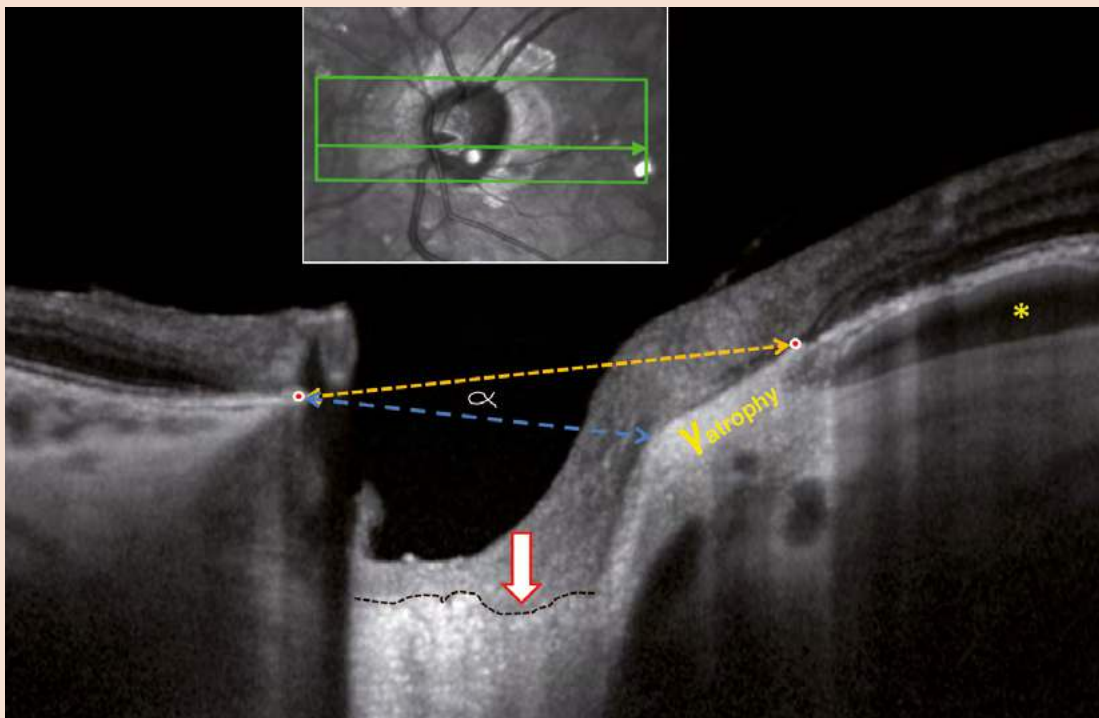


Figure 7. Enhanced depth imaging optical coherence tomography (EDI-OCT): Thanks to this technology, we can quantify the vertical and horizontal tilt angles objectively in a way that can be reproduced. The tilt angle is defined as the angle formed between the two lines that join the two ends of Bruch's membrane on the one hand (orange line) and the two rims of the disc (blue line) on the other. The degree of tilt defined in this way correlates with the degree of gamma peripapillary atrophy (where the sclera is missing both the retinal pigment epithelium and Bruch's membrane). Thinning of the lamina cribrosa (red arrow) and the presence of choroidal cavitation (*) are both commonly observed.

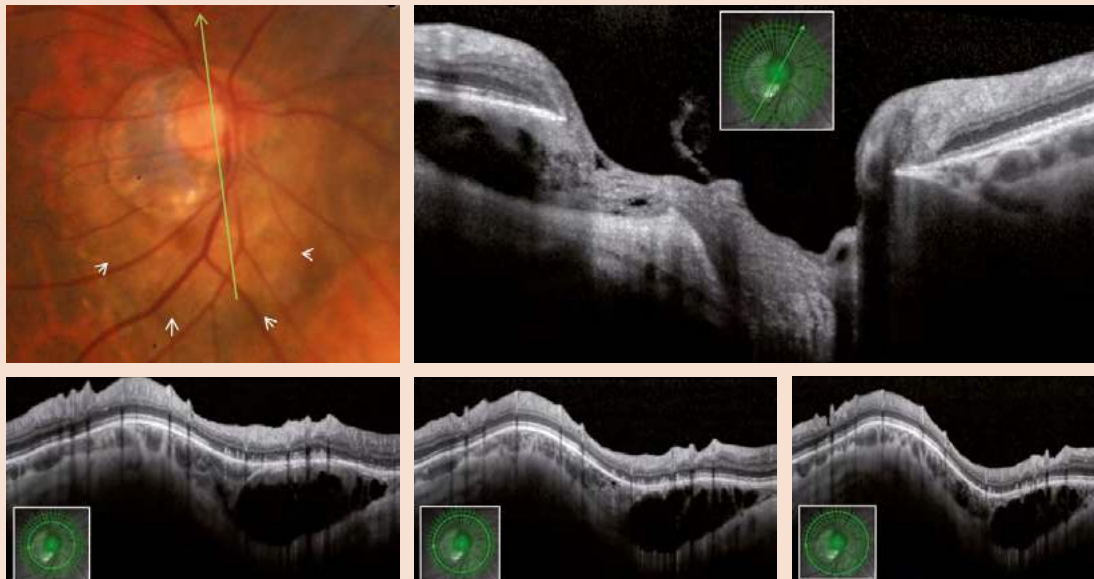


Figure 8. Tilted disc with choroidal cavitation (yellow/orange coloured area next to the myopic conus shown by the arrows), viewed using optical coherence tomography as a hyporeflective space both in radial cross-section, where the discontinuity of the neuroretinal rim can be observed in the area with the greatest traction, and in the three ring scans from lowest to highest eccentricity.

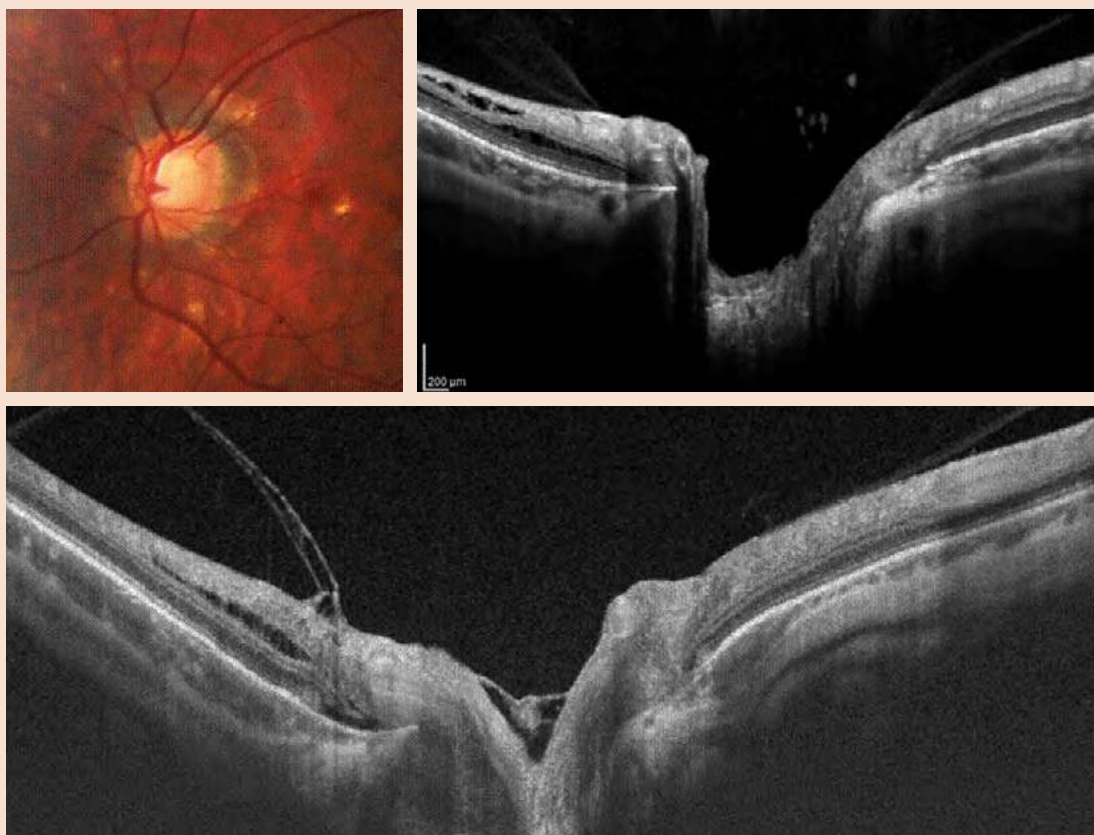
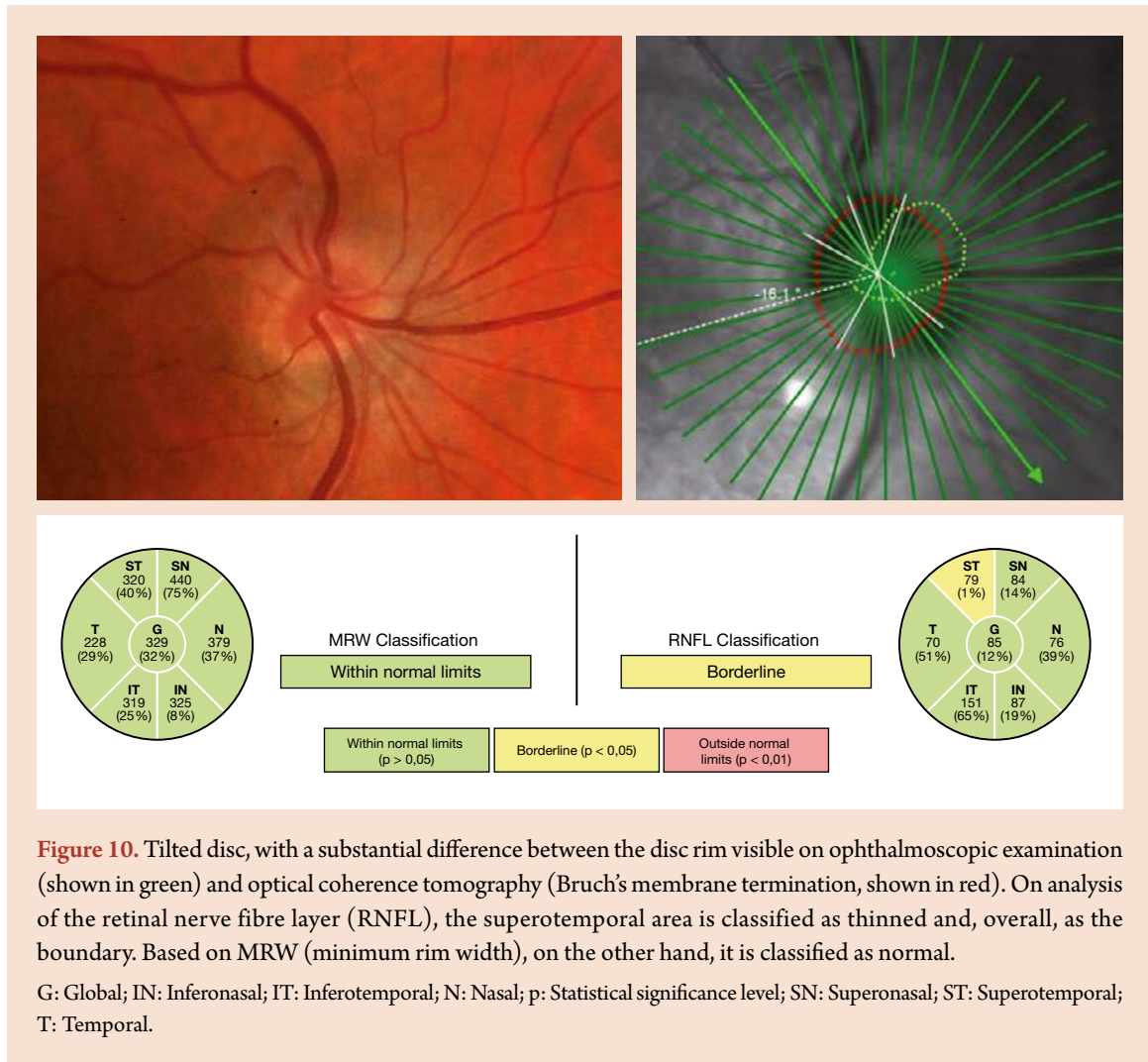


Figure 9. Tilted disc and myopia, with inner and outer retinoschisis examined using both enhanced depth imaging optical coherence tomography (EDI-OCT) (upper image) and swept-source optical coherence tomography (SS-OCT) (lower image).

- On examination, the retinal nerve fibre layer (RNFL) of such eyes is often abnormal. As false positives are common, examination results must be interpreted with caution. Due to their greater specificity for such cases, macular examination, exploration of the neuroretinal ring (minimum rim width – MRW) or a risk calculator are recommended (Fig. 10).



- Visual field defects usually appear in a variable percentage of cases, most frequently in the superotemporal region. Although there may be defects of all kinds, they can be corrected – at least to an extent – by means of suitable vision correction methods. In bilateral cases (bitemporal pseudo-hemianopia), it is useful to assess the failure to follow the vertical meridian. If in doubt, the neurological hemifield test (NHT) can be used.

Although visual field defects are not generally progressive (Figs. 11 and 12), new OCT technologies have demonstrated that the degree of optic disc tilt is an indirect marker of neuroretinal ring tension and determines the morphology and thickness of the lamina cribrosa, as well as the risk of glaucomatous progression, which would therefore have prognosis implications.

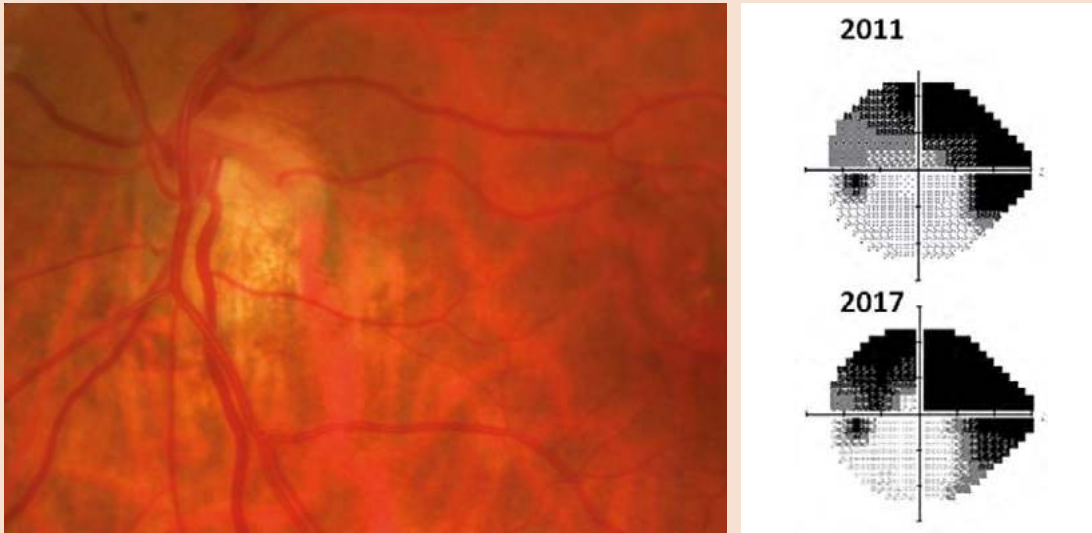


Figure 11. Visual fields for the tilted disc case shown in Figure 5. Stable lower nasal and upper altitudinal defect after six years of follow-up.

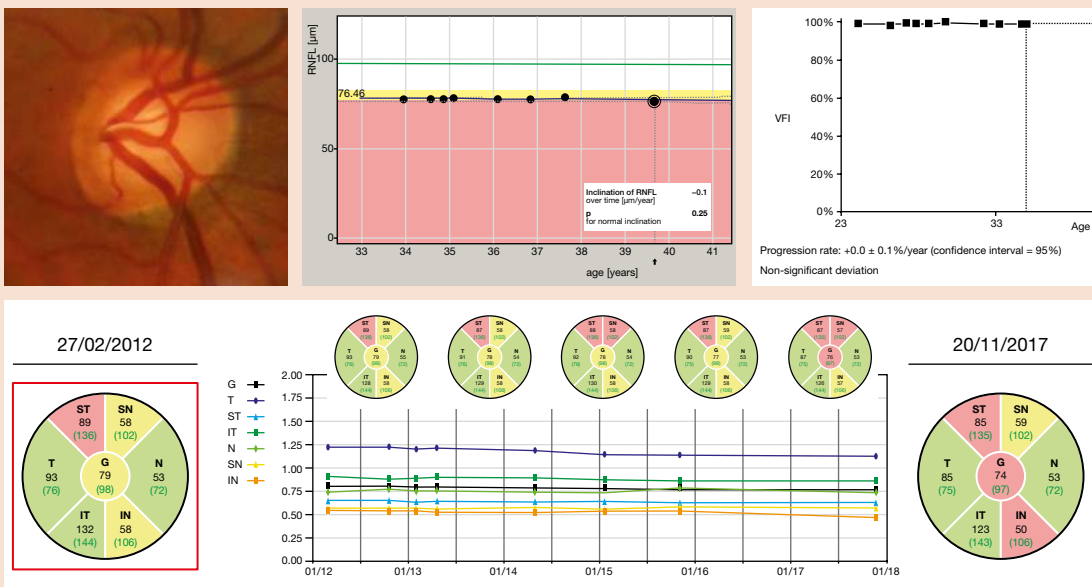


Figure 12. Tilted disc, with no significant changes either in perimetry over more than 10 years of follow-up, or in the analysis of the peripapillary retinal nerve fibre layer (RNFL) using Spectralis OCT in the last five years.

G: global; IN: inferonasal; IT: inferotemporal; N: nasal; p: statistical significance level; SN: superonasal; ST: superotemporal; t: time; T: temporal; VFI: visual field index.

- There may be various associated retinal disorders, including posterior staphyloma, changes in pigment, retinoschisis, detached retina, choroidal neovascularisation and chorioretinal folds (Fig. 6).

E

Differential Diagnosis

- Segmental optic disc hypoplasia.
- Optic disc oedema (unilateral), papilloedema, pseudopapilloedema (bilateral).
- Glaucoma.
- Optic disc of the myopic eye.

F

Ocular and Systemic Associations

- Optic nerve drusen (Fig. 13). Both of these fall under the differential diagnosis of optic disc pseudo-oedema.

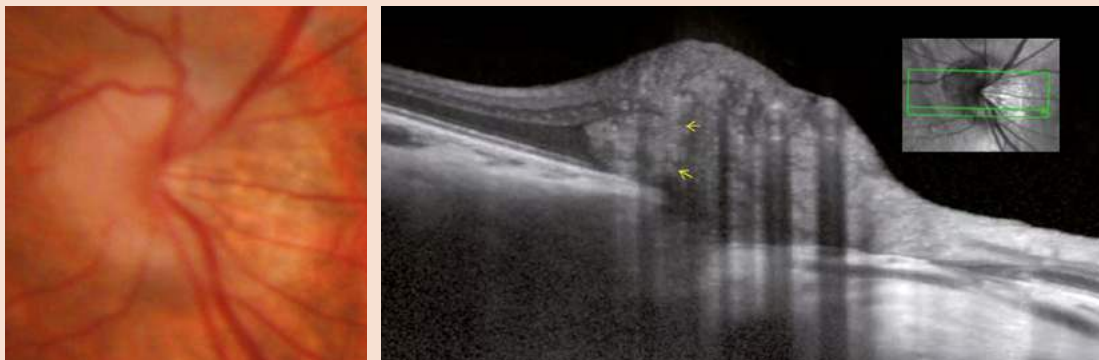

Figure 13. Tilted disc with a raised and blurred rim, with a peripapillary hyperreflective ovoid mass-like structure (PHOMS) shown on the OCT.

- Glaucoma: The high prevalence of glaucoma in myopic eyes with tilted disc, the difficulties involved in the clinical examination of the disc, and artefacts found on RFNL examination hinder diagnosis – and sometimes follow-up too.

G

Key Points

1

In bilateral cases, which can falsely look like a bitemporal visual field defect, it is imperative to rule out chiasm compression, and an NHT may be a good way to prioritise costs.



Bibliography

Han JC, Lee EJ, Kim SH, Kee C. Visual field progression pattern associated with optic disc tilt morphology in myopic open-angle glaucoma. *Am J Ophthalmol.* 2016;169:33-45.

Kim TW, Kim M, Weinreb RN, Woo SJ, Park KH, Hwang JM. Optic disc change with incipient myopia of childhood. *Ophthalmology.* 2012;119(1):21-6.e1-3.

Leal-Fonseca M, Rebolleda G, Oblanca N, Moreno-Montañés J, Muñoz-Negrete FJ. A comparison of false positives in retinal nerve fiber layer, optic nerve head and macular ganglion cell-inner plexiform layer from two spectral-domain optical coherence tomography devices. *Graefes Arch Clin Exp Ophthalmol.* 2014;252(2):321-30.

Lee JE, Sung KR, Lee JY, Park JM. Implications of optic disc tilt in the progression of primary open-angle glaucoma. *Invest Ophthalmol Vis Sci.* 2015;56(11):6925-31.

Lee KM, Lee EJ, Kim TW. Lamina cribrosa configuration in tilted optic discs with different tilt axes: a new hypothesis regarding optic disc tilt and torsion. *Invest Ophthalmol Vis Sci.* 2015;56(5):2958-67.

McCoy AN, Quigley HA, Wang J, Miller NR, Subramanian PS, Ramulu PY, et al. Development and validation of an improved neurological hemifield test to identify chiasmal and postchiasmal lesions by automated perimetry. *Invest Ophthalmol Vis Sci.* 2014;55(2):1017-23.

Moreno-Montañés J, Leal-Fonseca M, Oblanca N, Muñoz-Negrete FJ, Rebolleda G. A diagnostic calculator for detecting glaucoma and false positive using Cirrus OCT. *Invest Ophthalmol Vis Sci.* 2016;57(3):1052.

Park HY, Lee K, Park CK. Optic disc torsion direction predicts the location of glaucomatous damage in normal-tension glaucoma patients with myopia. *Ophthalmology.* 2012;119(9):1844-51.

Rebolleda G, Casado A, Oblanca N, Muñoz-Negrete FJ. The new Bruch's membrane opening – minimum rim width classification improves optical coherence tomography specificity in tilted discs. *Clin Ophthalmol.* 2016;10:2417-25.

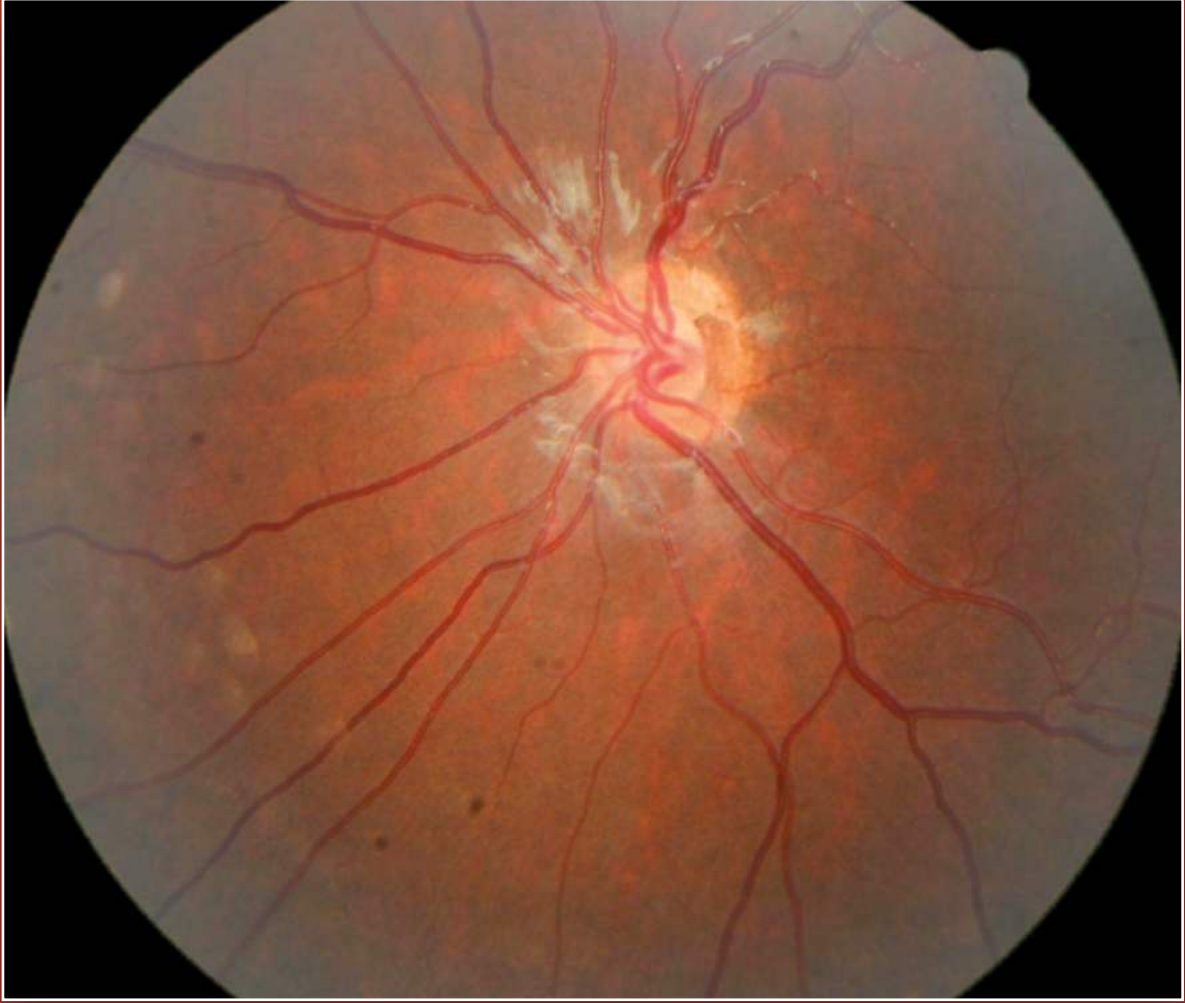Rebolleda Fernández G, Arrondo Murillo E, Muñoz-Negrete FJ. Análisis y estudio de la papila óptica y de la excavación en la alta miopía. In: Ruiz Moreno JM, Arias Barquet L (eds.). Actualización en patología retiniana de alta miopía. Official lecture in the 91st Congress of the Spanish Ophthalmology Society (SEO). Madrid: Sociedad Española de Oftalmología (SEO); 2015. p. 317-34.

Shin HY, Park HY, Park CK. The effect of myopic optic disc tilt on measurement of spectral-domain optical coherence tomography parameters. *Br J Ophthalmol.* 2015;99(1):69-74.

Shinohara K, Moriyama M, Shimada N, Nagaoka N, Ishibashi T, Tokoro T, et al. Analyses of shape of eyes and structure of optic nerves in eyes with tilted disc syndrome by swept-source optical coherence tomography and three-dimensional magnetic resonance imaging. *Eye (Lond).* 2013;27(11):1233-41; quiz 1242.

Tay E, Seah SK, Chan SP, Lim AT, Chew SJ, Foster PJ, et al. Optic disk ovality as an index of tilt and its relationship to myopia and perimetry. *Am J Ophthalmol.* 2005;139(2):247-52.

Witmer MT, Margo CE, Drucker M. Tilted optic disks. *Surv Ophthalmol.* 2010;55(5):403-28.



Optic Nerve Hypoplasia

María Isabel Canut Jordana
Andrés Fernández-Vega Cueto-Felgueroso
Gema Rebolleda Fernández

3

A

Definition

- Optic nerve hypoplasia (ONH) is the most common optic nerve anomaly and the main cause of congenital blindness in children. It can be either unilateral or bilateral, with considerable variation of clinical presentations and a variable degree of reduced visual acuity.
- It is non-progressive and characterised by fewer optic nerve fibres.
- It may manifest as an isolated ocular abnormality or in association with other neurological or endocrine disorders and developmental anomalies.
- Historically, ONH has been related to the absence of the septum pellucidum, known as septo-optic dysplasia or De Morsier syndrome. However, more recent studies suggest that they are two independent and unrelated phenomena.

B

Prevalence

- It ranges between 7.1/100000 and 10.9/100000 in Sweden and the United Kingdom, respectively.
- It accounts for approximately 10% of cases of bilateral congenital blindness and is the most frequent cause of legal blindness in children under three years of age in the United States.



Etiopathogenesis

- The main risk factor is being born to a young, primiparous mother, as well as prenatal exposure to cigarette smoking.
- There is insufficient evidence in medical literature of other likely factors, such as prenatal exposure to drugs and alcohol, although there is evidence that the mother's pregestational nutritional status could be a factor.
- Cases of ONH associated with endocrine disorders due to hypothalamic or pituitary dysfunction, responsible for non-visual morbidity, have been reported. Cases of growth hormone deficiency and corticotrophin deficiency, hypothyroidism and diabetes insipidus have also been reported.
- In unilateral ONH cases, hypothalamic/pituitary anomalies (69%) and delayed development (39%) are less common than in bilateral cases (81% and 78%, respectively).

D

Clinical Signs

- ONH may be unilateral (20%) or bilateral (80%) (in many cases, asymmetric), with variable degrees of visual acuity loss, which is more serious when the neural loss is greater. 80% of bilateral cases present with legal blindness, and the first sign is usually visual impairment in early childhood and associated sensory nystagmus, present from the first month of age.
- In monocular cases, we see strabismus (esotropia), relative afferent pupillary defect, unstable visual fixation of the affected eye and amblyopia that, in mild cases, may improve with occlusion (patching) of the healthy eye.
- The optic disc is usually small and grey in colour, surrounded by a ring of hyperpigmentation, caused by concentric chorioretinal atrophy ('double ring sign') (Figs. 1 and 2), although it is not specific, as it may appear in other vision disorders such as myopia.

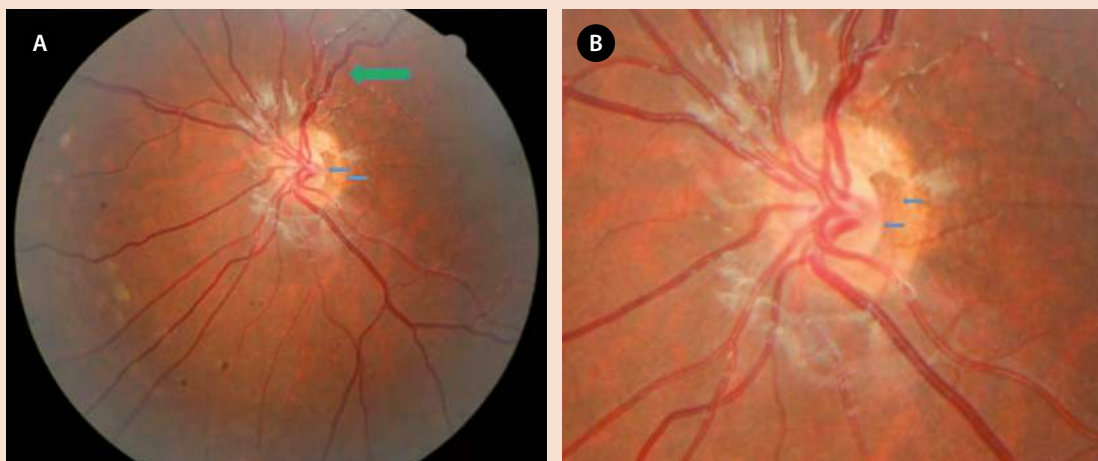


Figure 1. A: Optic nerve hypoplasia with a small, grey optic disc, surrounded by a ring of hypopigmentation or hyperpigmentation caused by concentric chorioretinal atrophy, also called 'double ring sign' (blue arrows). The green arrow shows the tortuous retinal vessels. **B:** Details of Figure 1A.

- Another characteristic sign is an increase of the distance between the fovea and optic disc when the disc-macula distance / disc diameter ratio is > 3 (Fig. 3).
- The calibre of retinal vessels is normal, although they are occasionally tortuous (considered a marker of endocrinopathy) (Fig. 1).
- There are other variable and unspecific signs that depend on the severity of the symptoms, such as the flattening of the contours of the macula, loss of foveal reflex, astigmatism, visual field defects, dyschromatopsia, microphthalmos, aniridia, albinism, high myopia, chorioretinal coloboma or topless disc syndrome, which is segmental optic disc hypoplasia (Fig. 2).

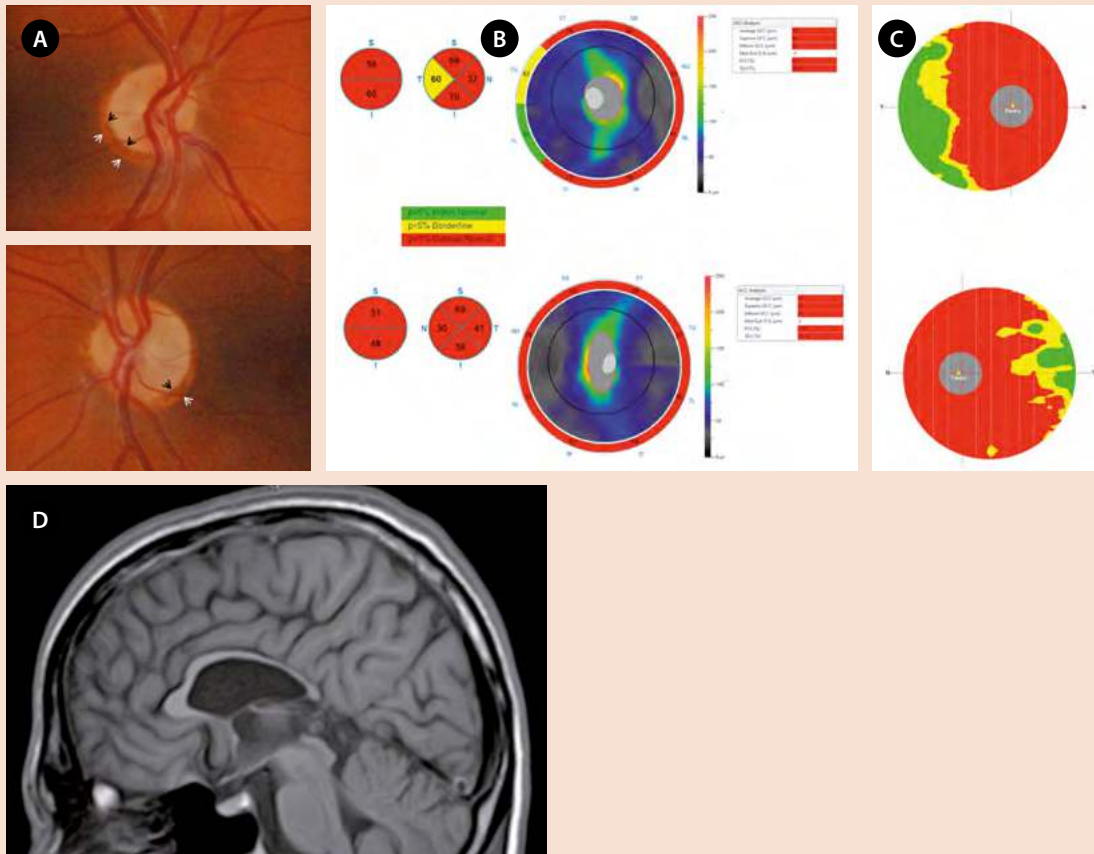


Figure 2. Bilateral optic nerve hypoplasia with the double ring sign (A), and significant thinning of the retinal nerve fibre layer (B) and macular ganglion cell complex (C) measured by Optovue optical coherence tomography. The FLAIR magnetic resonance imaging (D) shows a progressive thinning of the corpus callosum from the genu to the splenium.

FLV: focal loss volume; GCC: ganglion cell complex; GLV: global loss volume; I: inferior; IN: inferior nasal; IT: inferior temporal; N: nasal; NL: nasal lower; NU: nasal upper; p: level of statistical significance; S: superior; SN: superior nasal; ST: superior temporal; T: temporal; TL: temporal lower; TU: temporal upper.

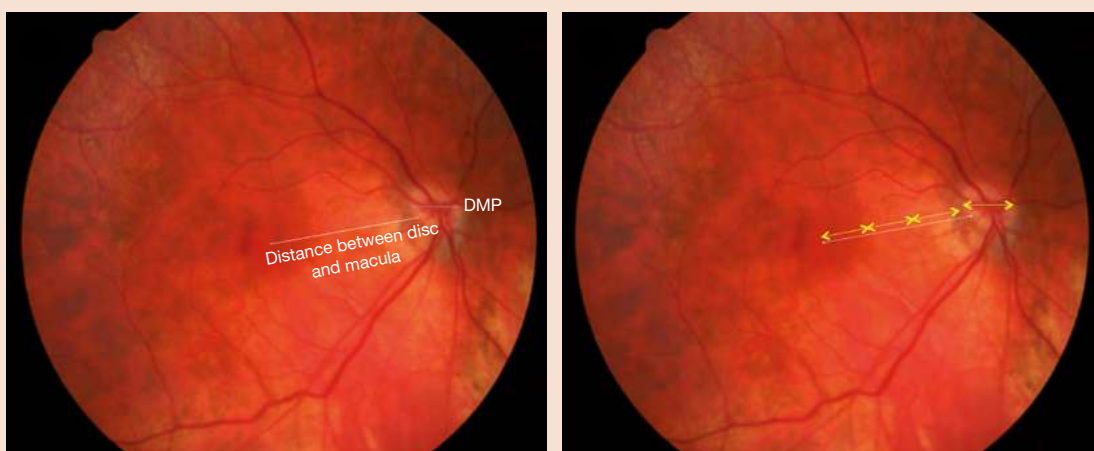


Figure 3. Optic nerve hypoplasia. The distance between the optic disc-macula / longest optic disc diameter is greater than 3.

- When studying the visual field, there is no single visual field defect pattern, and a diffuse or sectoral enlargement of the blind spot (Fig. 4 B), or arciform defects, can be seen.

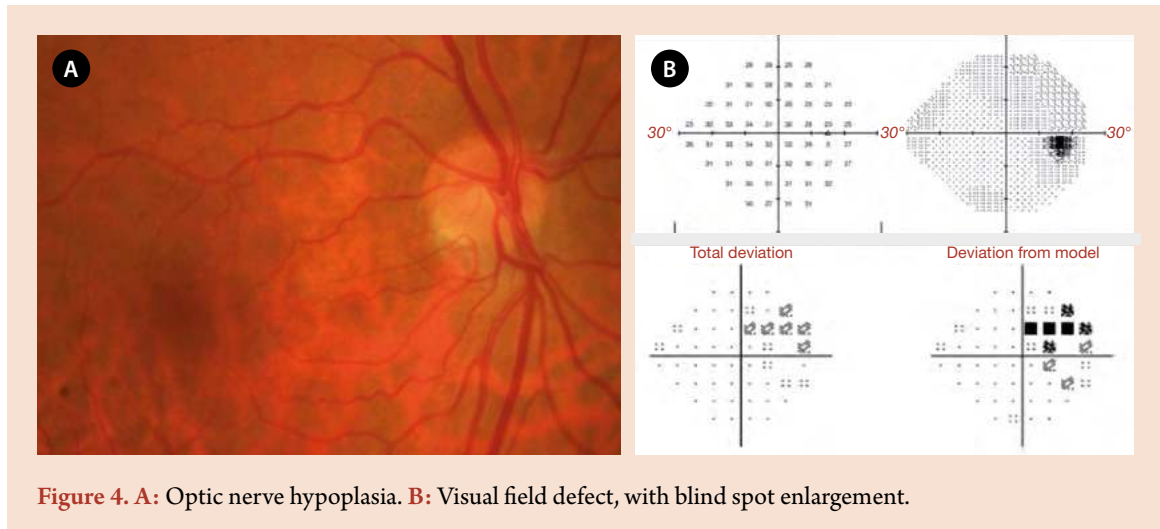


Figure 4. A: Optic nerve hypoplasia. B: Visual field defect, with blind spot enlargement.

- It is usually characterised by normal electroretinograms and electrooculograms, but the visual evoked potentials will be reduced according to the severity of the hypoplasia.
- The diameter of the disc is correlated with the degree of visual defect and the thickness of the retinal nerve fibre layer and macular ganglion cells as measured by optical coherence tomography (OCT). The thinner it is, the shorter the diameter of the disc (Fig. 2).

E

Differential Diagnosis

- Other optic neuropathies of a demyelinating, compressive or ischemic origin.
- Other congenital optic nerve defects.

F

Systemic Associations

A developmental delay, autism, partial or complete hypoplasia of the corpus callosum (Fig. 2), focal cortical dysplasia, grey matter heterotopia, agenesis of the septum pellucidum, hydrocephalus, white matter hypoplasia or arachnoid cysts can be observed. It may also be characterised by recurrent jaundice and hypoglycaemia, especially when they present with temperature instability.

G

Key Points

1

Optic nerve hypoplasia is usually part of a syndrome that includes developmental anomalies, hypothalamic dysfunction or neuroanatomical abnormalities. It is important to rule out hydrocephalus.

2

Normal pituitary function does not rule out the possibility of endocrine disorders.

3

The absence of septum pellucidum does not confer a prognostic value of the clinical abnormalities that could possibly be associated with it.

4

In cases of bilateral hypoplasia, it is advisable to carry out neuroradiological and endocrinological examinations.

5

The best-known risk factor is being a young, primiparous mother, as well as prenatal exposure to cigarette smoking.

6

The associated genetic base is not known.

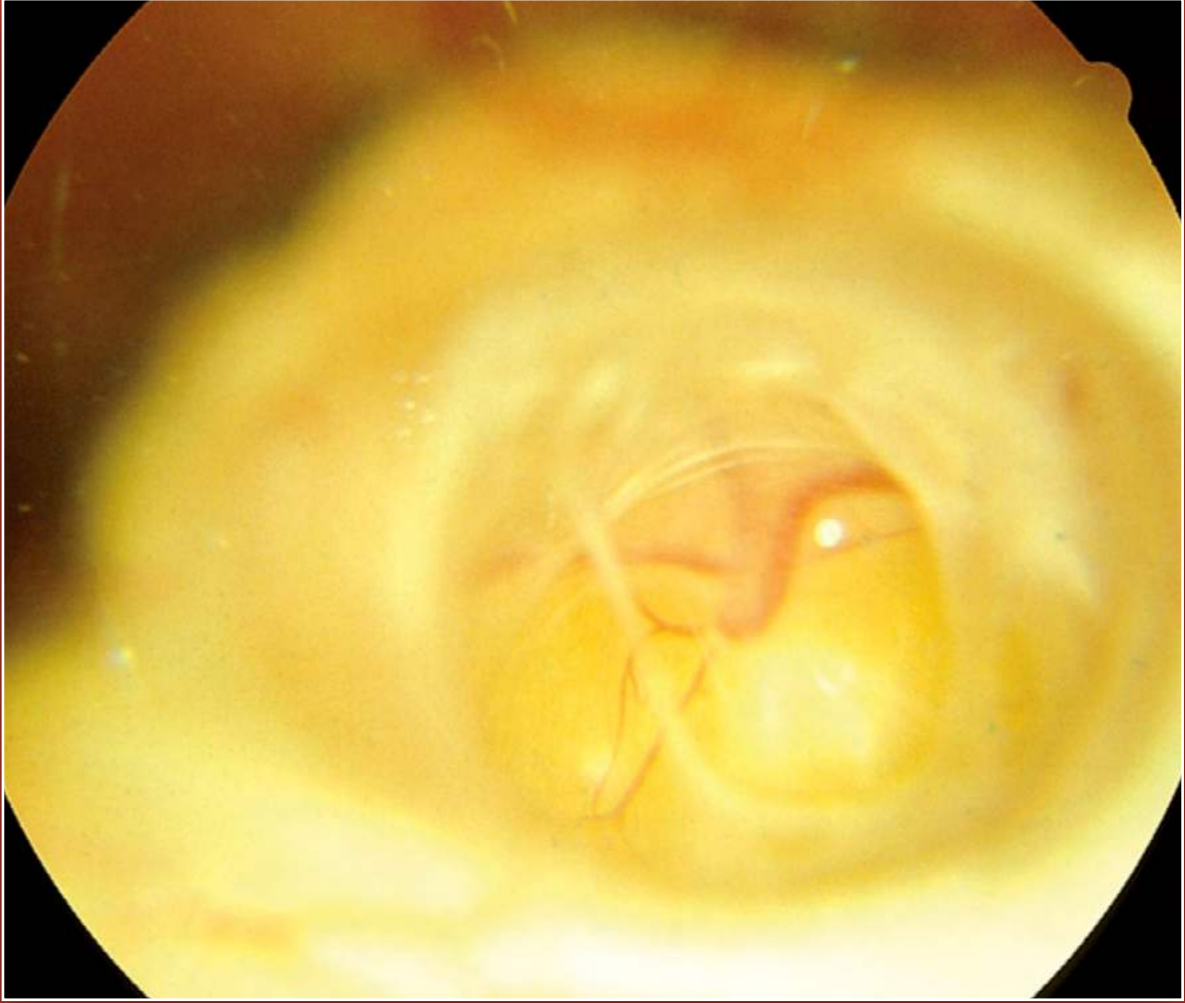
7

The diameter of the optic disc is correlated with the thickness of the retinal nerve fibre layer and retinal ganglion cells around the macula, assessed by OCT.



Bibliography

- Clemente-Tomás R, Ruíz-Del Río N, García-Ibor F, Duch-Samper AM. Unilateral optic nerve hypoplasia: optical coherence tomography and magnetic resonance imaging study. *Arch Soc Esp Ophthalmol*. 2018;93(6):e41-e42.
- Dahl S, Wickstrom R, Ek U, Tear Fahnehjelm K. Children with optic nerve hypoplasia face a high risk of neurodevelopmental disorders. *Acta Paediatr*. 2018;107(3):484-9.
- Garcia-Filion P, Borchert M. Optic nerve hypoplasia syndrome: a review of the epidemiology and clinical associations. *Curr Treat Options Neurol*. 2013;15(1):78-89.
- Kaur S, Jain S, Sodhi HB, Rastogi A, Kamlesh. Optic nerve hypoplasia. *Oman J Ophthalmol*. 2013;6(2):77-82.
- Kelly JP, Baran F, Phillips JO, Weiss AH. Optical coherence tomography in optic nerve hypoplasia: correlation with optic disc diameter, nerve fiber layer thickness, and visual function. *J Neuroophthalmol*. 2018;38(3):312-9.
- Khaper T, Bunge M, Clark I, Rafay MF, Mhanni A, Kirouac N, et al. Increasing incidence of optic nerve hypoplasia/septo-optic dysplasia spectrum: geographic clustering in Northern Canada. *Paediatr Child Health*. 2017;22(8):445-53.
- Sowka J, Vollmer L, Reynolds S. Superior segmental optic nerve hypoplasia: the topless disc syndrome. *Optometry*. 2008;79(10):576-80.



Optic Disc Coloboma

Andrés Fernández-Vega Cueto-Felgueroso
María Isabel Canut Jordana
Gema Rebolleda Fernández

4

A

Definition

Optic nerve coloboma is a congenital defect caused by defective closure of the embryonal fissure, which can occur as an isolated finding (Fig. 1) or associated with other eye colobomas, including iris, lens or chorioretinal coloboma (Figs. 2 and 3). The appearance of optic disc coloboma may vary from a notch in the ring to a complete excavation (Figs. 1-3) and may be unilateral or bilateral (50%).

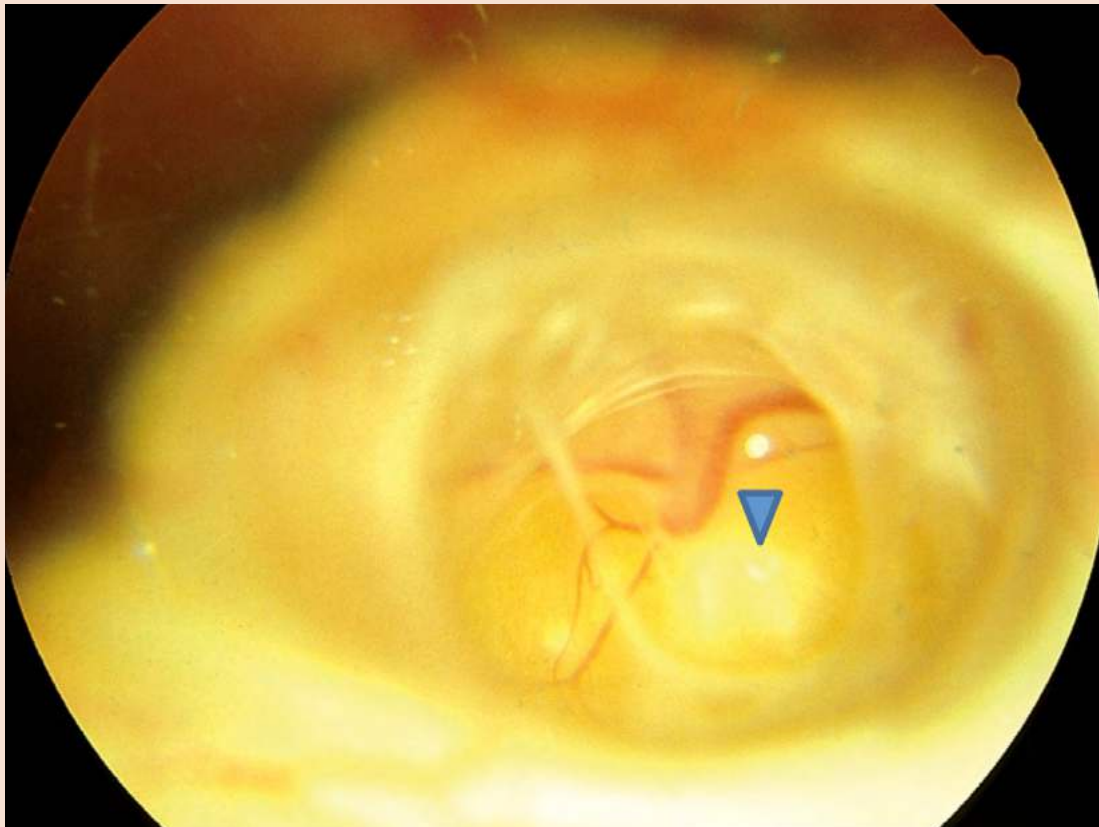


Figure 1. Optic disc coloboma (blue arrow). A white, bowl-shaped excavation in the optic nerve can be observed.

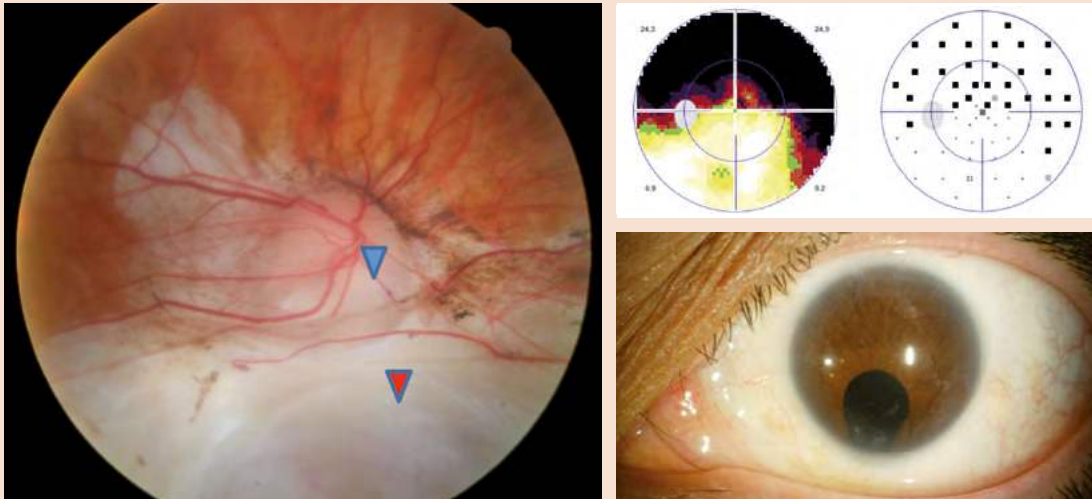


Figure 2. Optic disc coloboma (blue arrow), associated with an inferior chorioretinal coloboma (red arrow), with superior chorioretinal atrophy. It is associated with a typical iris-lens coloboma in the inferior nasal quadrant. Superior altitudinal visual field defect related to a retinal coloboma.

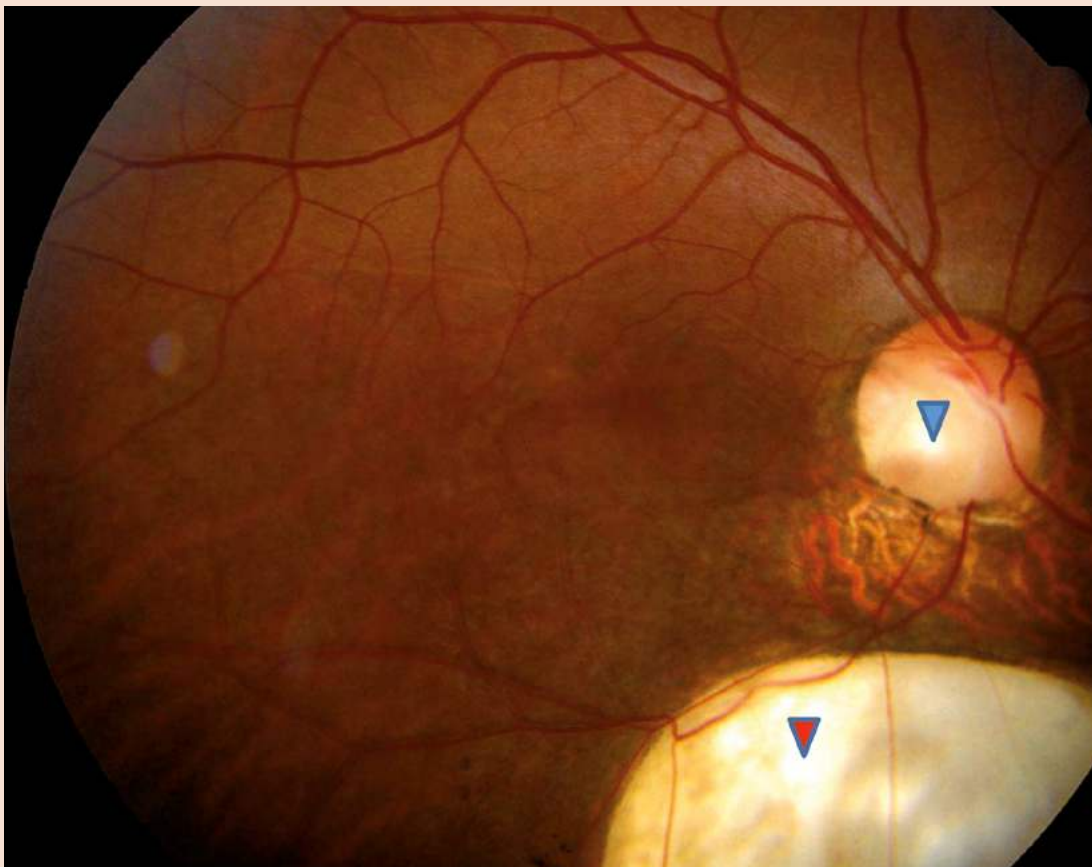


Figure 3. Optic disc coloboma (blue arrow) associated with an inferior chorioretinal coloboma (red arrow) and peripapillary atrophy in the bridge region.

B

Etiopathogenesis

Prevalence of optic disc coloboma is low (0.14%). It is the result of an incomplete closure of the most proximal end of the embryonic cleft, which normally occurs in the seventh week of gestation. Colobomas are usually sporadic, although cases of autosomal dominant inheritance associated with the PAX2 gene have been reported.



Clinical Signs

- The loss of visual acuity is variable and is related to the integrity of the papillomacular bundle.
- The glistening white and deeply colobomatous excavation is usually well defined and, as a general rule, located in the inferior section with a thinned or non-existent neuroretinal rim (Figs. 2 and 3). Sometimes the defect can be filled with glial tissue or herniated retinal tissue.
- It may be isolated (Fig. 1), associated with other colobomas (Figs. 2 and 3) or microphthalmia or be part of congenital syndromes.
- In cases associated with large chorioretinal coloboma, leukocoria can be seen.
- Fluorescein angiography shows hypofluorescence in the coloboma region.
- Optical coherence tomography (OCT) helps to determine the depth of the excavation, as well as assess whether there are any associated complications (retinoschisis, retinal detachment, choroidal neovascularisation).
- OCT angiography (OCTA) is useful for obtaining a differential diagnosis of morning glory disc anomaly, given the absence of the peripapillary vascular network.
- The associated visual field defects may be variable and, on occasion, mimic glaucomatous defects or other optic neuropathies (Fig. 2). Furthermore, a progressive increase of the colobomatous excavation in cases of autosomal dominant inheritance that is not linked to an increase in intraocular pressure has been described, making differential diagnosis more difficult.
- It may be associated with non-rhegmatogenous retinal detachment (Fig. 4), peripapillary choroidal neovascularisation, optic nerve cysts that could suggest the presence of compressive optic neuropathy, strabismus, nystagmus or lenticonus posterior.

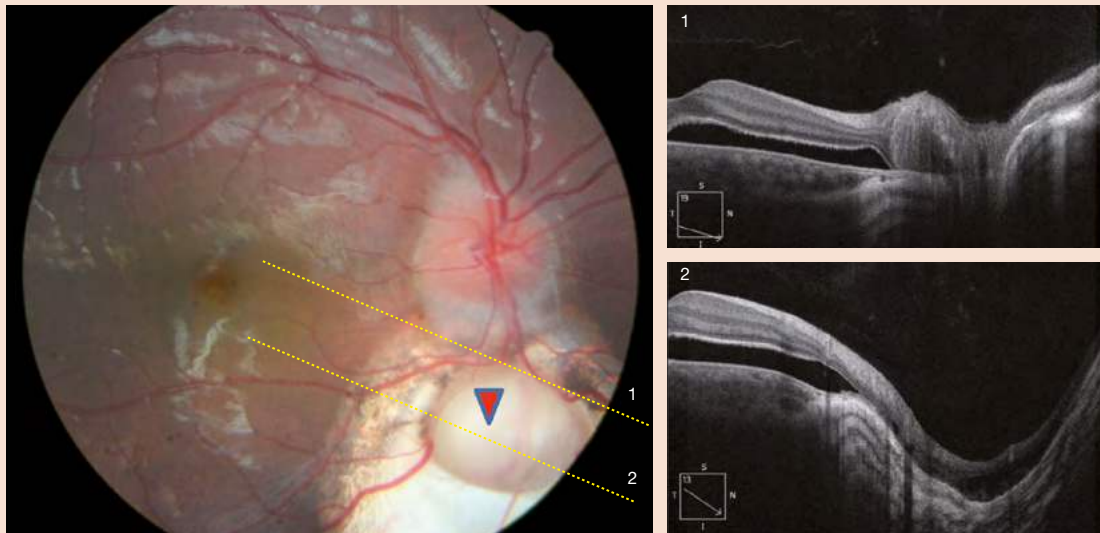


Figure 4. Inferior chorioretinal coloboma (red arrow) associated with a flat detachment of the temporal neurosensory retina. CIRRUS™ OCT: The scan of the bridge region shows the associated temporal detachment (1); the cut in the coloboma also shows the large chorioretinal excavation (2).

D

Differential Diagnosis

- Glaucomatous excavation.
- Morning glory.
- Optic disc pit.

E

Systematic Associations

- CHARGE syndrome (coloboma, heart defects, atresia choanae, retardation of growth and development, genital and ear abnormalities), associated with mutations in the CHD7 gene.
- Chromosomal abnormalities: Patau syndrome (trisomy 13), Edwards syndrome (trisomy 18) or cat eye syndrome (trisomy 22).
- Goldenhar syndrome (craniofacial microsomia, ocular dermoid cysts and vertebral anomalies).
- Dandy-Walker syndrome.

F

Key Points

1

Optic disc coloboma is a rare congenital ocular defect that occurs during embryogenesis, between the 5th and 7th weeks of gestation.

2

It may be associated with other ocular colobomas and/or systemic malformations. It is important to examine whether there may be associated chromosomal anomalies.

3

Due to the risk of retinal detachment, regular monitoring is essential.

4

Malformation syndromes require a multidisciplinary approach.

Babalola YO, Olawoye OO, Idam PO. Optic disc coloboma in two Nigerian siblings: case report and review of literature. *Niger J Clin Pract.* 2017;20(11):1505-9.

Beby F. Systemic abnormalities in children with congenital optic disc excavations. *Curr Eye Res.* 2015;40(4):450-5.

Chen YN, Patel CK, Kertes PJ, Devenyi RG, Blaser S, Lam WC. Retinal detachment and retrobulbar cysts in a large cohort of optic nerve coloboma. *Retina.* 2018;38(4):692-7.

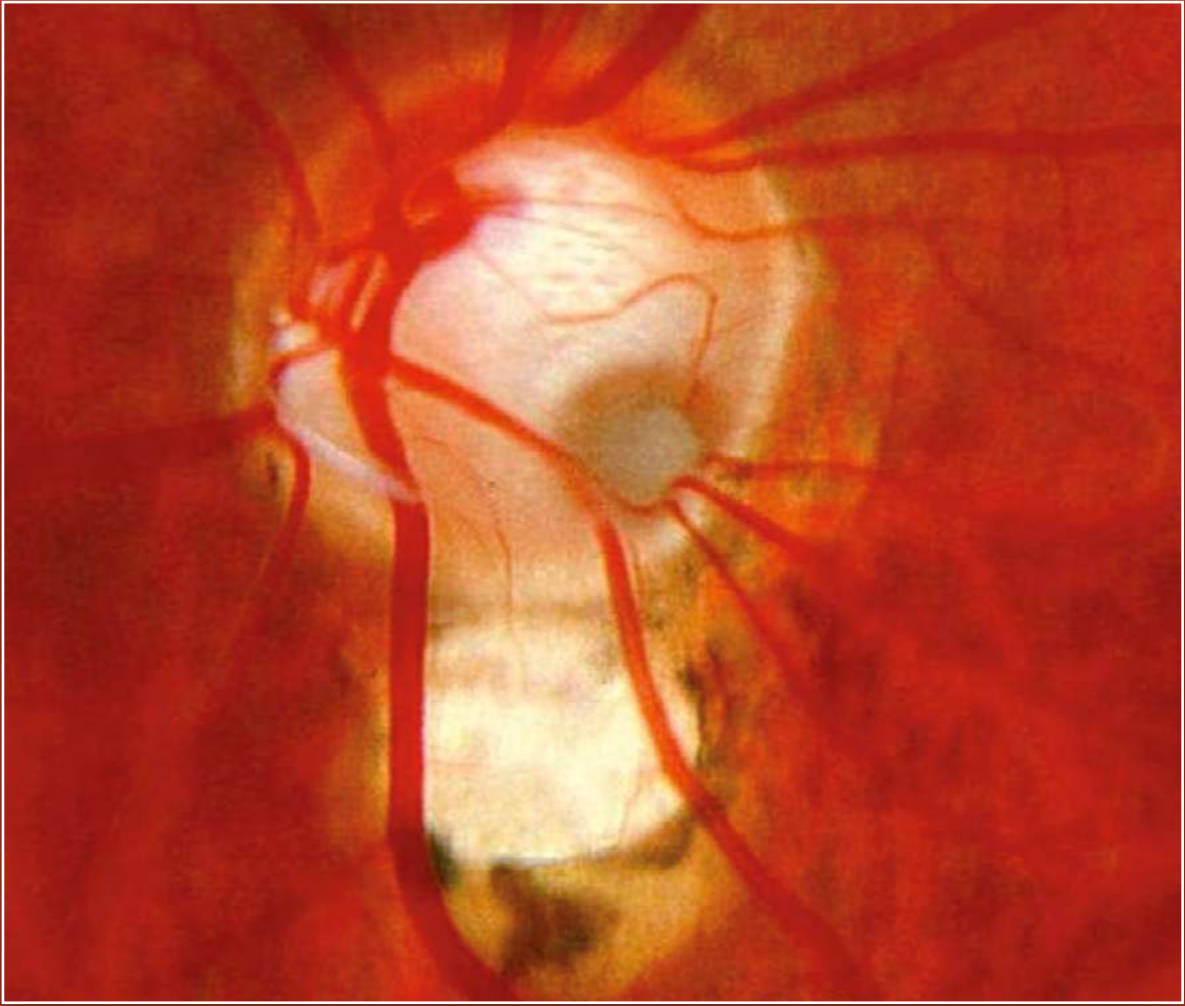
Gregory-Evans CY, Williams MJ, Halford S, Gregory-Evans K. Ocular coloboma: a reassessment in the age of molecular neuroscience. *J Med Genet.* 2004;41(12):881-91.

Jongmans MC, Admiraal RJ, Van der Donk KP, Vissers LE, Baas AF, Kapusta L, et al. CHARGE syndrome: the phenotypic spectrum of mutations in the CHD7 gene. *J Med Genet.* 2006;43(4):306-14.

Pastora N, Peralta J, Abelairas J. Isquemia retiniana y proliferación fibrovascular tardía asociada a coloboma de nervio óptico. *Arch Soc Esp Oftalmol.* 2016;91(4):184-7.

Pujari A, Singh R, Regani H, Agrawal S. Bilateral optic disc coloboma. *BMJ Case Rep.* 2017;2017:bcr2017221547.

Takkar B, Venkatesh P, Agarwal D, Kumar A. Optic disc coloboma with pit treated as glaucoma: diagnostic utility of ultrasound and swept source optical coherence tomography. *BMJ Case Rep.* 2017;2017.



Congenital Optic Disc Pit

**María Isabel Canut Jordana
Andrés Fernández-Vega Cueto-Felgueroso
Gema Rebolleda Fernández**

5

A

Definition

Congenital optic disc pits are rare (prevalence 1:11 000) and occur equally in men and women. They are often unilateral, although in 10% to 15% of cases they may be bilateral (Fig. 1). They are seen as a greyish-whitish round or oval focal depression in the optic disc, normally located in the temporal quadrant of the optic disc, although they may be seen in any sector (Fig. 2).

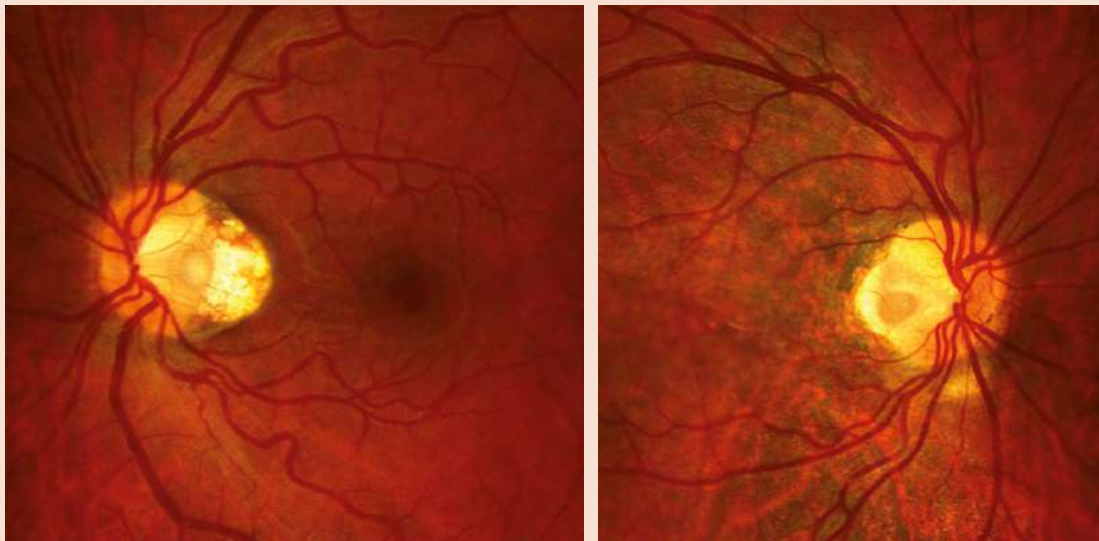


Figure 1. Congenital optic disc pit, located in the temporal sector.

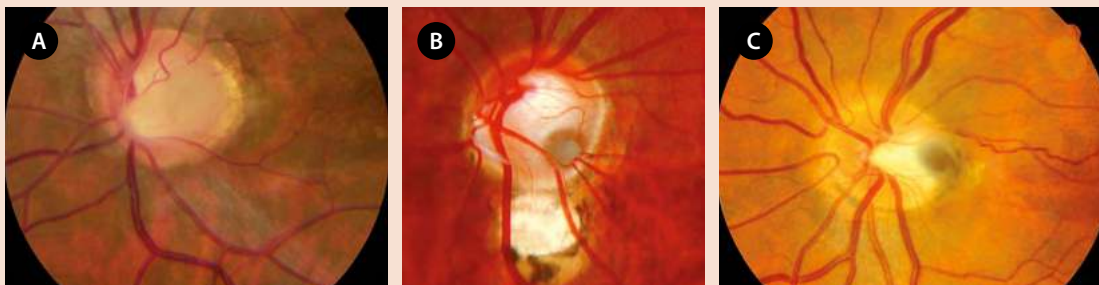

Figure 2. Congenital optic disc pits in the left eye. Characteristic aspect of a greyish-whitish crater-shaped oval (A) or round (B and C) depression, located in the temporal sector.

B

Etiopathogenesis

Although there is controversy, recent studies suggest that, unlike optic disc coloboma, congenital optic disc pits are not due to the abnormal closure of the optic fissure. Histologically and using swept-source optical coherence tomography (SS-OCT), it has been shown that they are associated with defects and/or disinsertions of the lamina cribrosa. The presence of one or more chorioretinal arteries is common, and the disc is somewhat larger than usual (Fig. 2 C).

C

Classification

It is important to differentiate between a congenital pit and a glaucoma-related pseudo-pit or acquired colobomatous pit. Although the two entities may be indistinguishable on clinical examination, both their location and the accompanying clinical pattern help in the differential diagnosis.

Congenital pits are more frequently located in the temporal or inferotemporal quadrant of the optic disc (70%) (Figs. 2 and 3). However, acquired pits are linked to glaucomatous optic neuropathy and are usually seen in the superior (Figs. 4 and 5) or inferior border of the optic disc, frequently associated with optic disc haemorrhages. They are more often seen in normal tension glaucoma and focal ischemic glaucoma.

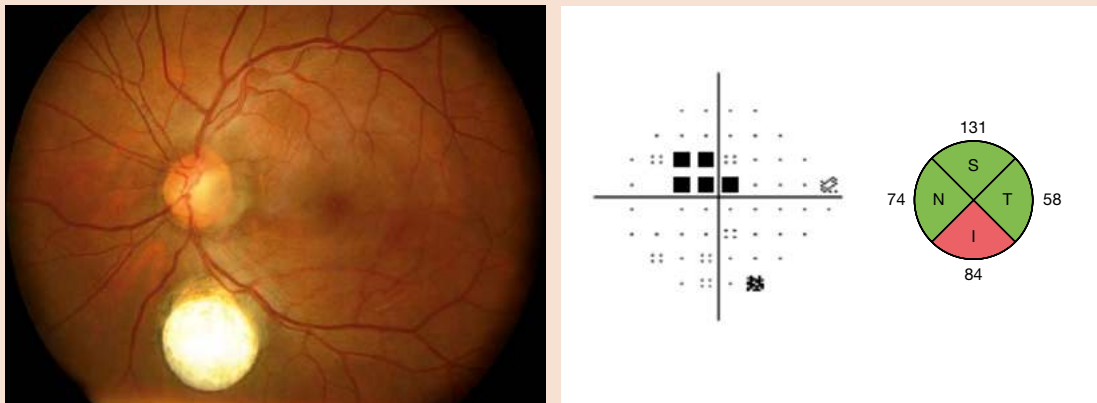


Figure 3. 23-year-old woman with an inferotemporal oval depression in the left optic disc, corresponding to an inferior sectoral thinning of the retinal nerve fibre layer, observed using optical coherence tomography, with a central superior haemiscotoma compatible with congenital pit. It is associated with an inferior nummular patch of chorioretinal atrophy.

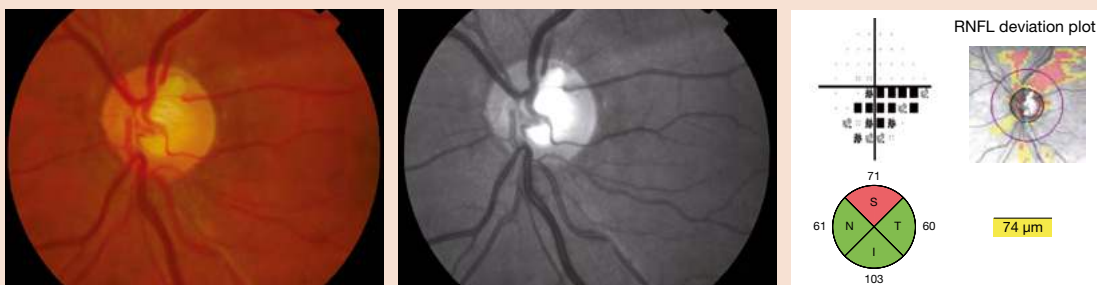

Figure 4. Superior glaucomatous acquired optic disc pit, with a notch in the superior neuroretinal rim and significant thinning of the superior retinal nerve fibre layer (RNFL), using both Stratus optical coherence tomography (OCT) and CIRRUS™ OCT, and its corresponding defect on the inferior border.

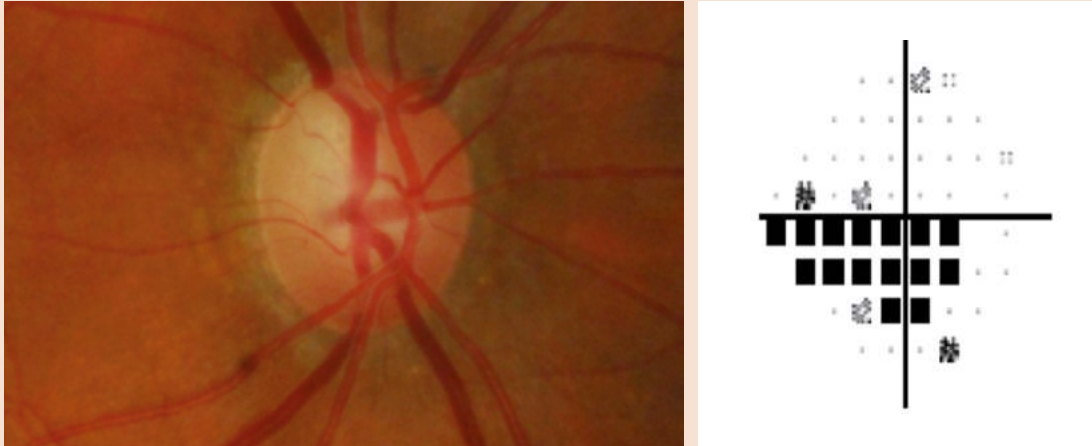


Figure 5. Superior pseudo-pit in a primary open-angle glaucoma, with a notch in the superior neuroretinal rim and the corresponding defect on the inferior border.

It is of utmost importance to make a correct diagnosis in order to establish the precise hypotensive treatment and reduce the glaucoma progression rate. Determining the cause of progression is more complicated when both entities are present (Fig. 6).

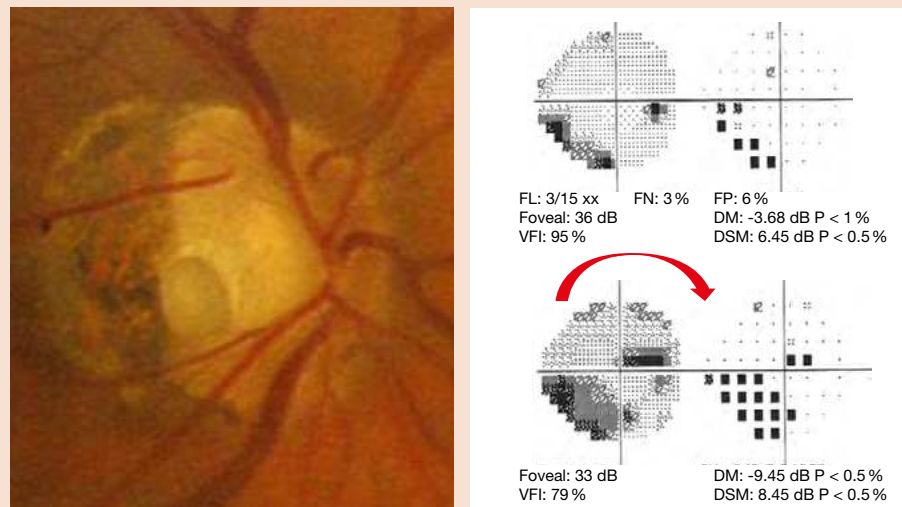


Figure 6. Patient with a typical congenital pit in the right eye and a concomitant primary open-angle glaucoma. In this case, deterioration of the margin can be observed due to badly managed intraocular pressure. There is no associated maculopathy, but a progressive thinning of the superior neuroretinal rim with the corresponding inferior arcuate defect can be observed.

D

Clinical Signs

- The majority are located in the temporal quadrant, with a typical clinical appearance (70%) (Figs. 1, 2, 3 and 6); 20% are found in the centre (Fig. 7) and 10% in other locations.

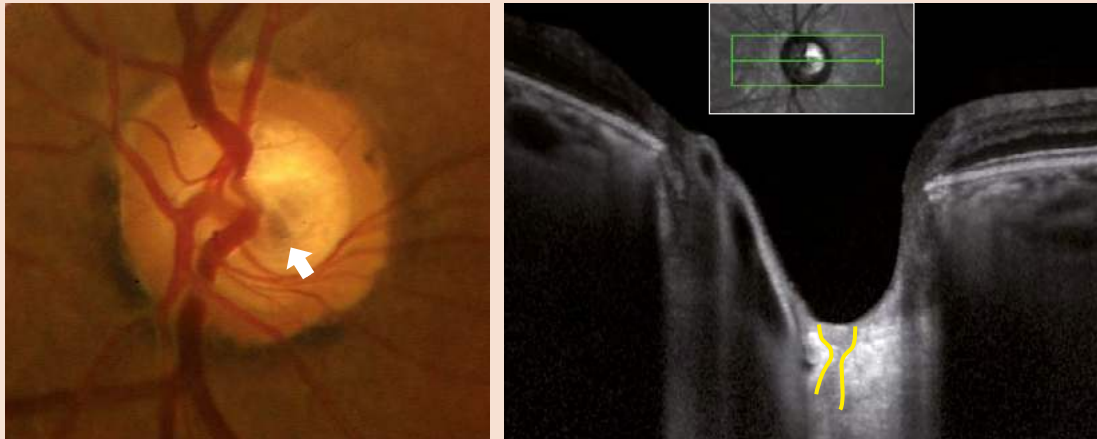


Figure 7. Central congenital pit showing the morphology of the cavity and the associated lamina cribrosa defect, using EDI-OCT technology (enhanced depth imaging optical coherence tomography).

- Visual acuity is usually normal, with no complications or associated ocular diseases.
- Associated macular changes are common, either as a serous detachment or as cystoid macular oedema (Figs. 8 and 9). Although there is controversy on the matter, the fluid may be of cerebrospinal origin, due to communication with the subarachnoid space as a result of the defect in the lamina cribrosa and/or vitreous body. A serous detachment of the macula can be observed in 30%-45% of eyes of people with a mean age of 30. Although cases of spontaneous resolution have been reported, the majority require surgery to prevent irreversible damage.
- Central congenital pits (Fig. 7), which account for 20% of cases, are not usually associated with maculopathy and are difficult to differentiate from glaucomatous excavations, a complexity that increases as 75% of patients will develop glaucoma in adulthood.
- Visual field defects associated with congenital pits may mimic glaucomatous defects (Fig. 3).
- OCT is very useful for assessing the morphology, depth and width of the cavity, observing whether or not there are defects in the lamina cribrosa (Figs. 7 and 10) or herniation of the neural tissue and to determine the distance to the subarachnoid space, in order to gain a better understanding of the pathogenesis. It is likewise useful for assessing whether or not it is associated with maculopathy (Figs. 8 y 9), since areas of macular retinoschisis are often seen prior to the serous detachment. Greater vitreo-papillary adhesion has been reported in these eyes.

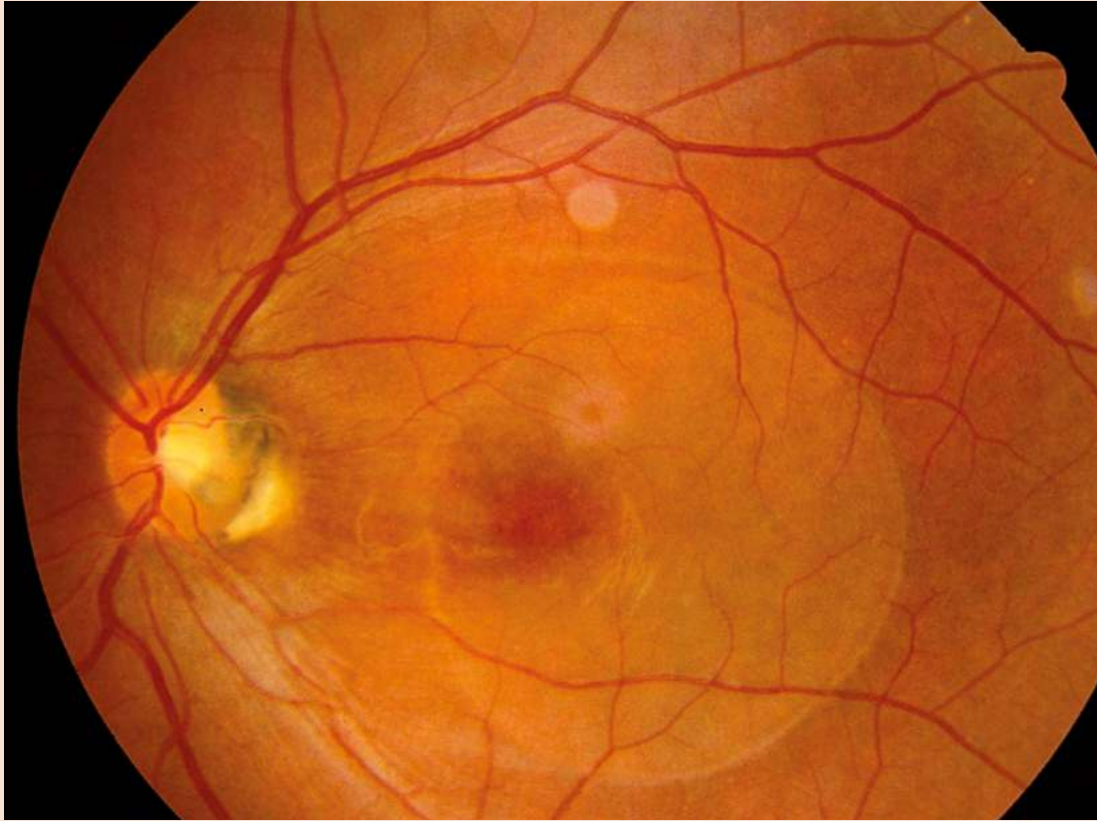


Figure 8. Congenital pit associated with a serous detachment of the macula with variable widths and heights.

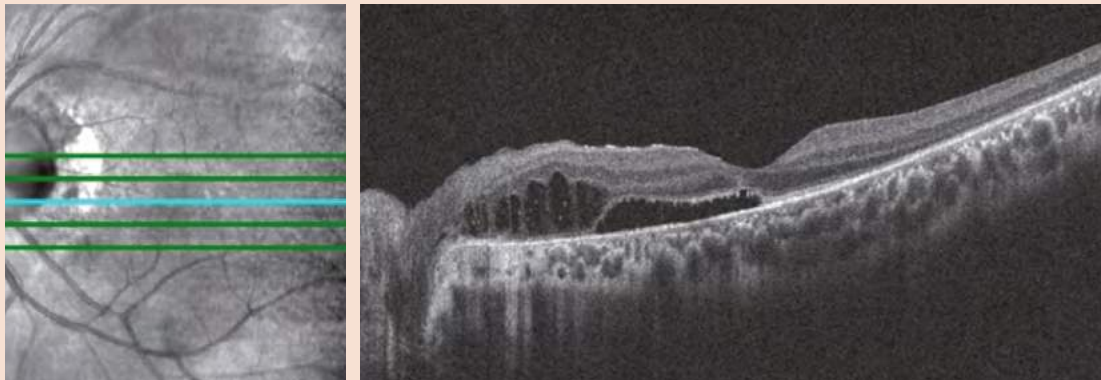
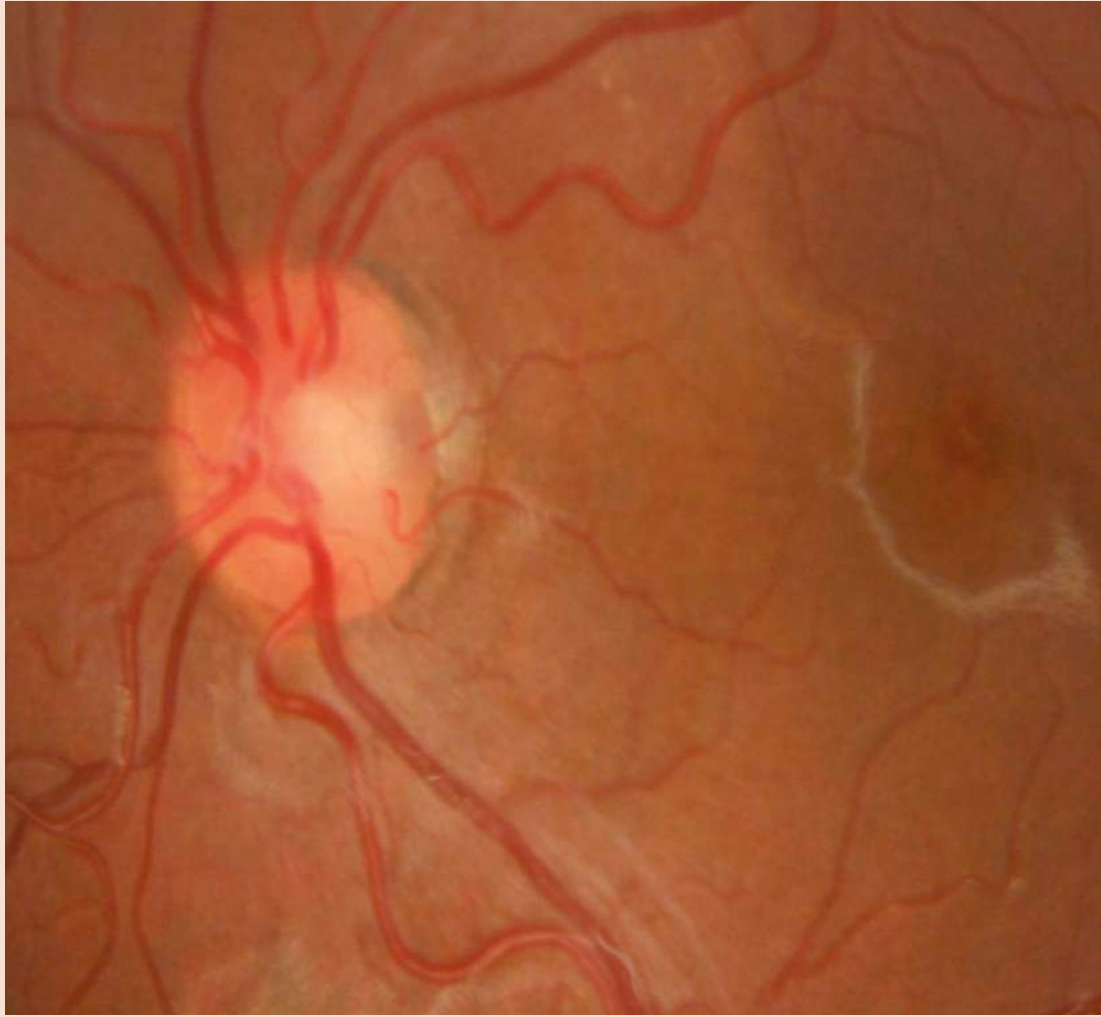


Figure 9. Congenital pit associated with retinoschisis, visible by optical coherence tomography.

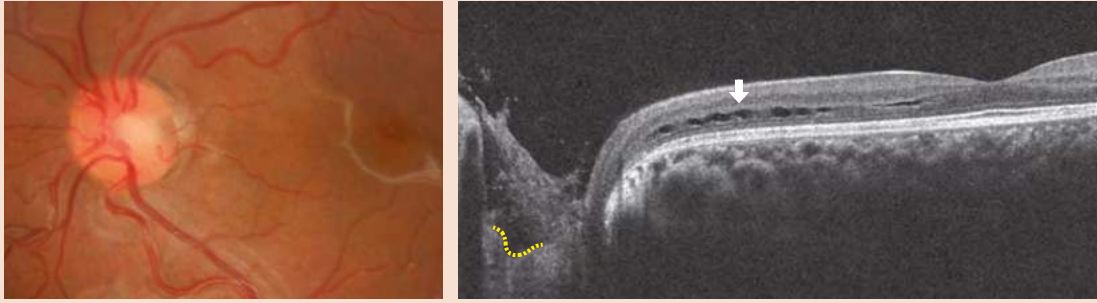


Figure 10. Temporal congenital pit, where the focal depression at the level of the lamina cribrosa (yellow dotted line), herniation of the neural tissue and internal peripapillary retinoschisis can be observed.

E

Differential Diagnosis

- Optic disc coloboma.
- Optic nerve hypoplasia.
- Morning glory anomaly.
- Glaucomatous optic disc and myopic conus pits.

F

Systemic Associations

Fairly rare, although cases of Alagille and Aicardi syndromes have been reported.

G

Key Points

1

A rare entity, often asymptomatic and discovered by chance.

2

It is important to differentiate it from glaucoma-related acquired pseudopits, which usually occur at the vertical poles.

3

OCT is used to define associated structural defects (lamina cribrosa, peripapillary region) and gain a better understanding of the origin of subretinal fluid.

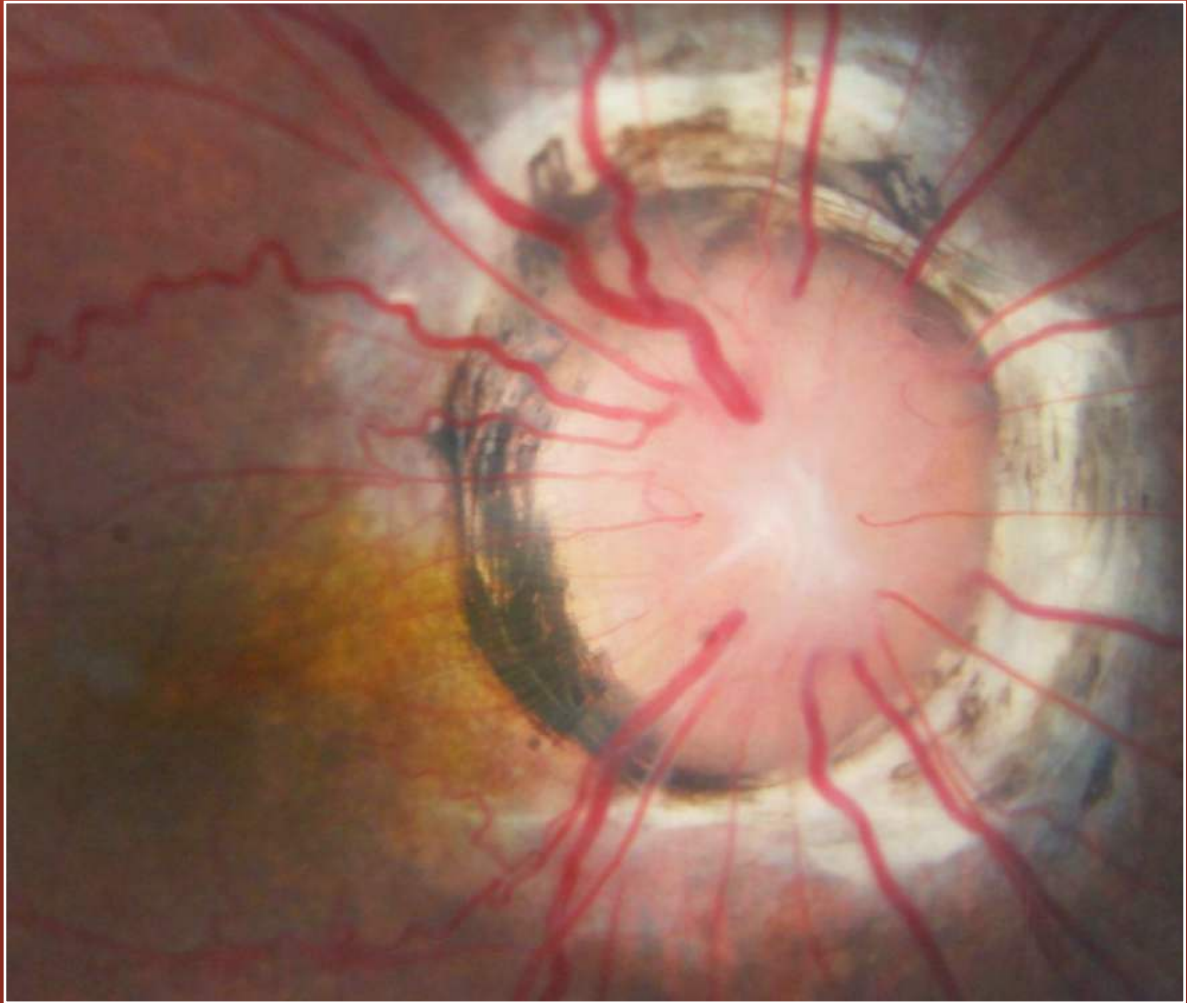
4

When associated with glaucoma, the treatment aims to reduce intraocular pressure; when there are complications with maculopathy, a surgical approach is required.



Bibliography

- Dhir L, Thaller VT. Unilateral optic disc pit and orbital cyst in an eye with normal axial length. *Ophthalmic Plast Reconstr Surg*. 2010;26(3):217-8.
- Georgalas I, Ladas I, Georgopoulos G, Petrou P. Optic disc pit: a review. *Graefes Arch Clin Exp Ophthalmol*. 2017;249(8):1n3-22.
- Jeng-Miller KW, Cestari DM, Gaier ED. Congenital anomalies of the optic disc: insights from optical coherence tomography imaging. *Curr Opin Ophthalmol*. 2017;28(6):579-86.
- Koulouri I, Gaier ED, Elliott D, Vavvas DG. Double optic disc pit with glial plugs imaged by wide-field optical coherence tomography. *Ophthalmic Surg Lasers Imaging Retina*. 2018;49(1):52-4.
- Nagesha CK, Ganne P. Occult optic disc pit maculopathy in a glaucomatous disc. *Middle East Afr J Ophthalmol*. 2017;24(3):165-6.
- Nair AG, Kaliki S, Mishra DK, Naik MN. Unilateral optic disc pit associated with orbital cyst in a child. *Saudi J Ophthalmol*. 2017;31(3):190-2.
- Ohno-Matsui K, Hirakata A, Inoue M, Akiba M, Ishibashi T. Evaluation of congenital optic disc pits and optic disc colobomas by swept-source optical coherence tomography. *Invest Ophthalmol Vis Sci*. 2013;54(12):7769-78.
- Qayum S, Sullivan T, Park SC, Merchant K, Banik R, Liebmann JM, et al. Structure and clinical significance of central optic disc pits. *Ophthalmology*. 2013;120(7):1415-22.
- Saurabh K, Roy R, Shah D, Sinha Roy S. Multicolour imaging in a patient with optic disc pit maculopathy. *Clin Exp Optom*. 2018;101(6):805-6.



Morning Glory Disc Anomaly

Andrés Fernández-Vega Cueto-Felgueroso
Gema Rebolleda Fernández
María Isabel Canut Jordana

6

A

Definition

A very rare congenital anomaly (2.6/100000 newborn babies), named after the appearance of the disc resembling the flower of the same name. It is characterised by an enlarged optic disc with a large excavation, peripapillary pigmentary changes and the presence of a central white glial tuft, with radiating vessels arranged in an abnormal manner.

B

Etiopathogenesis

A sporadic anomaly of the optic nerve that is predominantly unilateral and has no gender predilection. Although there is disagreement around it, the most accepted hypothesis is that the condition is a primary neuroectodermal anomaly that causes a dilation of the terminal optic stalk and a secondary postnatal mesenchymal abnormality.

C

Clinical Signs

- Visual acuity is usually greatly reduced; only 30% of sufferers reach a vision of ≥ 0.5 and, in many cases, there is no correlation with the appearance of the optic disc.
- The diagnosis is eminently clinical due to the associated morphological characteristics. The optic disc is large, has an excavation and is surrounded by a peripapillary ring with variable degrees of chorioretinal atrophy. A characteristic feature is the central whitish-greyish glial tuft linked to persistent hyaloid remnants. As a general rule, the blood vessels leave the excavation in a straight line and arteries cannot be distinguished from veins (Fig. 1).

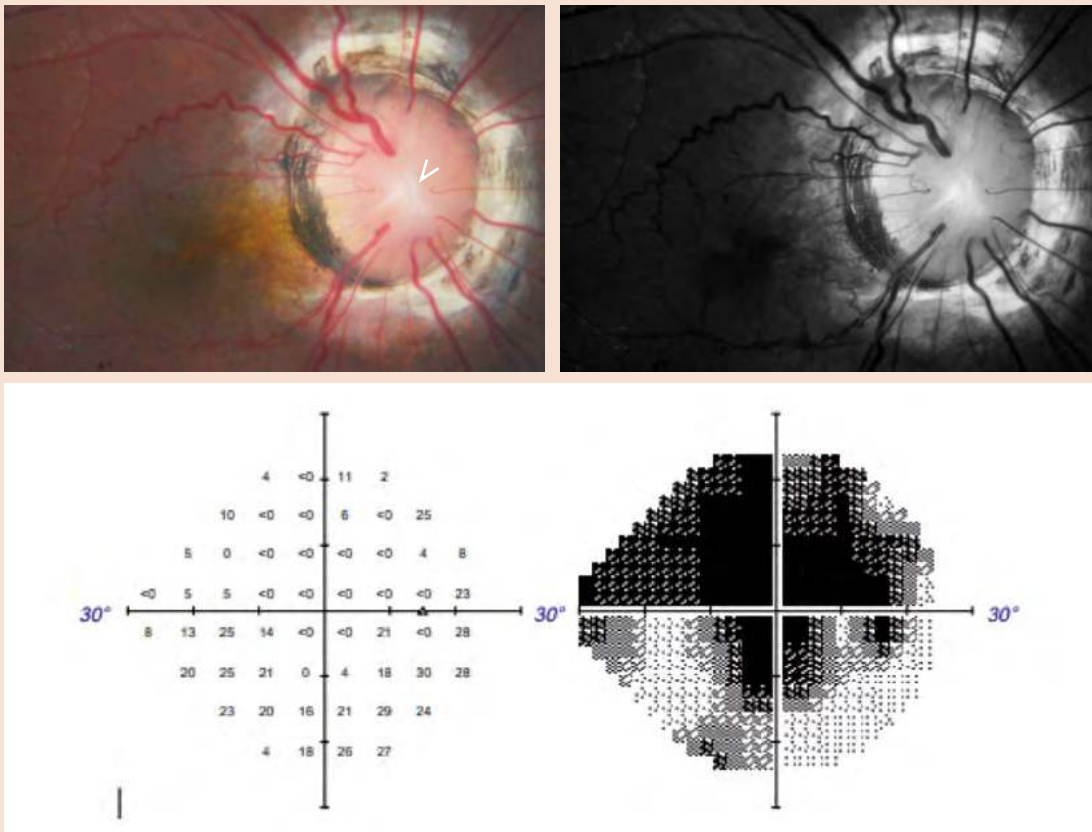


Figure 1. Characteristic aspect of a **morning glory optic nerve head**, with an enlarged optic disc, significant chorioretinal peripapillary atrophy and a central glial tuft (arrow), with vessels following a typical radial path. It is associated with a severe visual field defect.

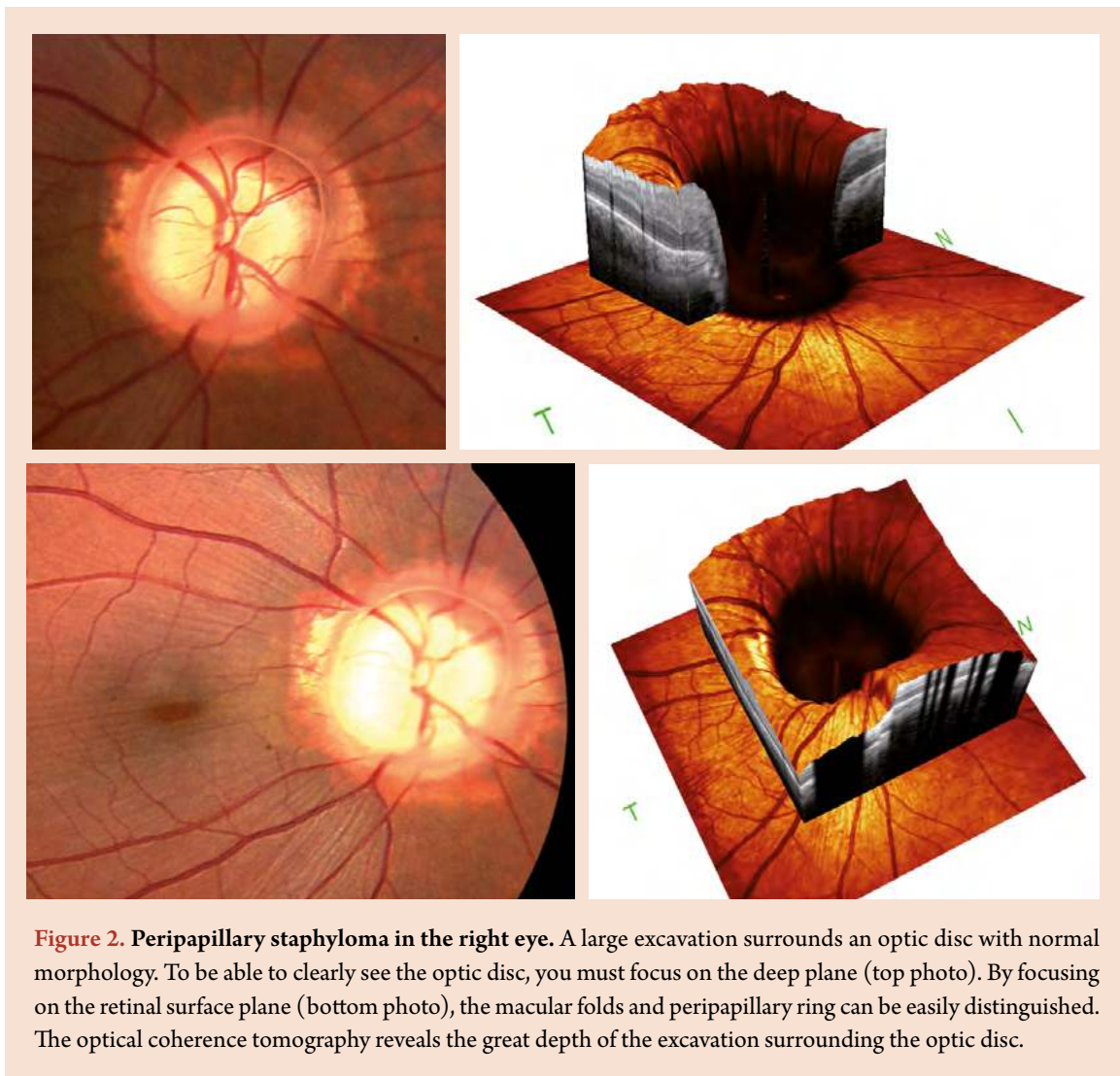
- A serous detachment of the retina can be observed in as many as 30% of cases and, more rarely, a rhegmatogenous retinal detachment, generally related to peripapillary traction, can be found.
- It can be associated with strabismus, amblyopia, nystagmus, refractive defects and often myopia or leukocoria, which lead to the diagnosis.

- The most frequent visual field anomalies are a centrocecal scotoma or an increase of the blind spot, although severe defects may also be observed (Fig. 1).
- Optical coherence tomography (OCT) is useful for differential diagnosis with other excavated congenital entities, such as optic disc coloboma, peripapillary pit or staphyloma.
- OCT makes it possible to obtain better knowledge of the pathogenesis of the anomaly and its complications. Thus, communications between the subretinal space and the subarachnoid space or vitreous chamber have been reported in the associated retinal detachment.
- OCTA confirms the presence of a peripapillary microvasculature that is characteristic of this entity and not present in other anomalies (colobomas and pits), which supports the aforementioned hypothesis of a primary neuroectodermal disorder with a secondary mesenchymal abnormality.
- It may be associated with other congenital ocular abnormalities such as cataracts, coloboma of the crystalline lens, lenticonus, aniridia, foveal hypoplasia, cysts of the ciliary body, persistent pupillary membrane, Bergmeister's papilla, microphthalmos, haemangioma of the eyelid, optic nerve drusen and glioma, as well as peripapillary neovascularisation.
- It is advisable to carry out neuroimaging examinations (magnetic resonance angiography) to rule out any associated neurological diseases.

D

Differential Diagnosis

- Optic disc coloboma.
- Peripapillary staphyloma: with a large excavation surrounding a disc and frequently with a normal appearance (Fig. 2).



- Renal coloboma syndrome (mutation of the PAX2 gene): Unlike morning glory, in such cases, the central vessels are absent, and the peripheral vessels emerge from the superior and inferior poles of the disc.
- Other causes of leukocoria (retinoblastoma, persistent myelinated fibres, toxocariasis, etc.).

E

Systemic Associations

Up to 45% of cases may be associated with cerebrovascular anomalies:

- Basal encephalocele.
- Hypopituitarism.
- Moyamoya disease.
- Craniofacial defects of the facial midline and agenesis of the corpus callosum.
- Neurofibromatosis type 2.
- PHACE neurocutaneous syndrome (posterior fossa anomalies, haemangioma, arterial anomalies, cardiac anomalies, and ocular and sternum defects).
- CHARGE syndrome (coloboma of the iris or retina, heart defects, atresia choanae, retardation of growth and development, genital hypoplasia and ear malformations).

F

Key Points

1

It constitutes an infrequent congenital anomaly of the optic nerve.

2

The diagnosis is essentially clinical, although OCT may be important to understand the pathogenesis of this entity and may be of help in making a differential diagnosis with other malformations.

3

The associated amblyopia requires early detection and treatment.

4

Screening is important to detect the presence of other systemic and ocular anomalies.

5

Regular monitoring is required due to the greater risk of serous retinal detachment.



Bibliography

Cavazos-Adame H, Olvera-Barrios A, Martínez-López-Portillo A, Mohamed-Hamsho J. Morning glory disc anomaly, a report of a successfully treated case of functional amblyopia. *J Clin Diagn Res.* 2015;9(10):ND01-3.

Cennamo G, Rossi C, Ruggiero P, De Crecchio G, Cennamo G. Study of the radial peripapillary capillary network in congenital optic disc anomalies with optical coherence tomography angiography. *Am J Ophthalmol.* 2017;176:1-8.

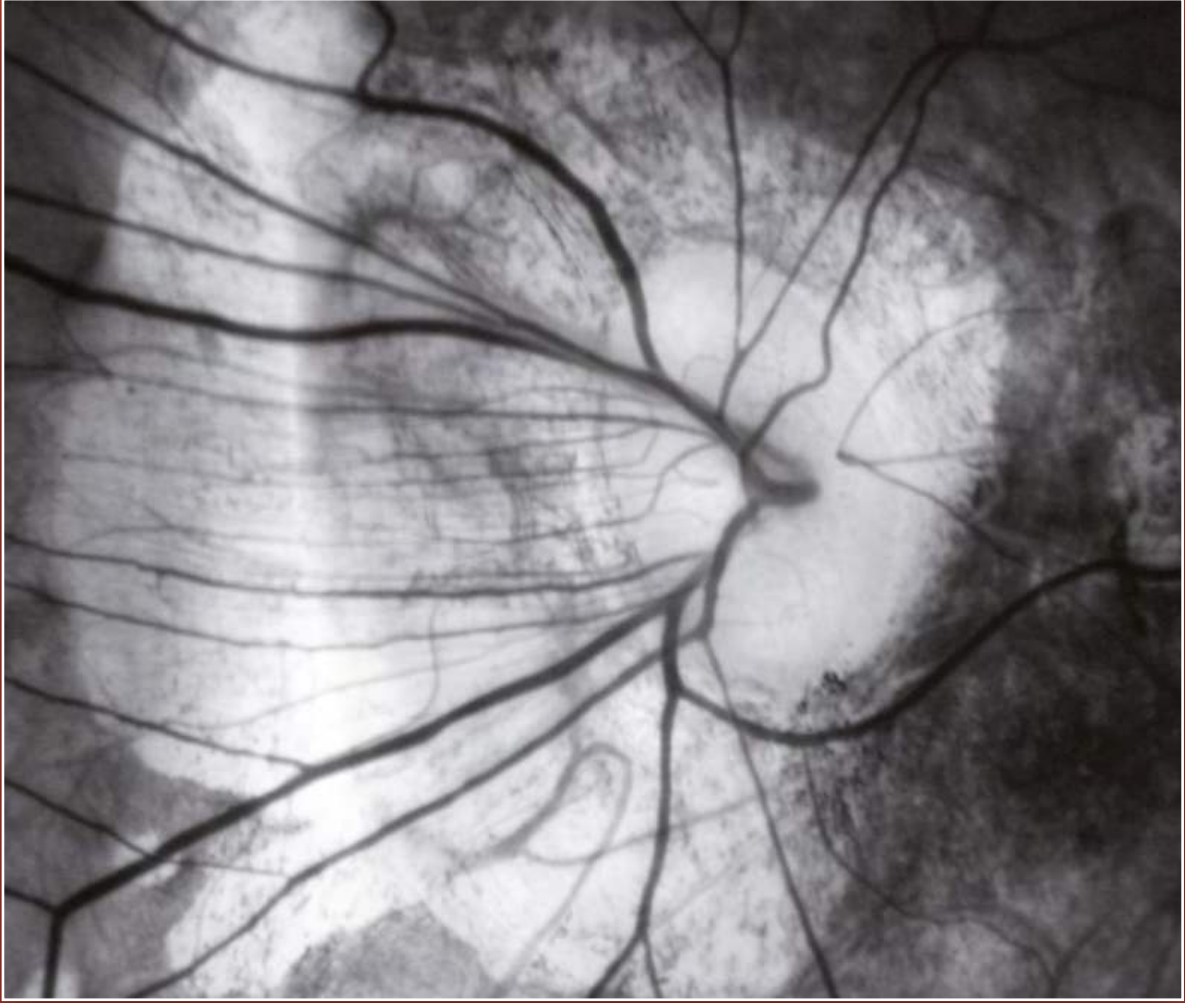
Ceynowa DJ, Wickstrom R, Olsson M, Ek U, Eriksson U, Wiberg MK, et al. Morning glory disc anomaly in childhood - a population-based study. *Acta Ophthalmol.* 2015; 93(7):626-34.

Jeng-Miller KW, Cestari DM, Gaier ED. Congenital anomalies of the optic disc: insights from optical coherence tomography imaging. *Curr Opin Ophthalmol.* 2017;28(6): 579-86.

Kniestedt C, Landau K, Brodsky MC, North P, Waner M. Infantile orofacial hemangioma with ipsilateral peripapillary excavation in girls: a variant of the PHACE syndrome. *Arch Ophthalmol.* 2004;122(3):413-5.

Lee BJ, Traboulsi EI. Update on the morning glory disc anomaly. *Ophthalmic Genet.* 2008;29(2):47-52.

Thoma D, Nijs I, Demaerel P, Casteels I. Morning glory disc anomaly with an ipsilateral enlargement of the optic nerve pathway. *Eur J Paediatr Neurol.* 2017;21(5):787-91.



High Myopia

Marta Mármol Díaz
María Isabel Canut Jordana

7

A

Definition

Myopia is the most common refractive error and one of the greatest causes of impaired vision. High myopia is defined as an eye with a refractive error higher than -6.0 dioptres and an axial length of ≥ 26.0 mm. Pathologic or degenerative myopia is characterised by progressive anteroposterior elongation of the globe, which is associated with secondary changes affecting the sclera, optic nerve, choroid, Bruch's membrane and retinal pigment epithelium (RPE).

B

Etiopathogenesis and Prevalence

Myopia has a multifactorial aetiology. Several loci associated with high myopia, including 18p11.31 (MYP2), 12q23.1-q24 (MYP3), 11p13 (MYP7), 3q26 (MYP8) and 4q12 (MYP9), have been studied. At present, myopia affects over a quarter of the population in Europe and the United States, with a higher than 70% prevalence in the urban areas of Asian countries. Its global incidence is growing, along with an increased frequency of visual complications such as myopic macular degeneration, glaucoma and retinal detachment.

C

Clinical Signs

Myopic eyes frequently present disc anomalies (Fig. 1):

- Increased vertical/horizontal disc diameter ratio.
- Flattening of the temporal quadrant of the optic disc, which causes the physiological excavation to disappear.
- Tilted or oblique disc (see Chapter 2). These are optic discs with a usually inferonasal scleral crescent or border, an irregular vascular pattern of the vessels that exit the optic disc (situs inversus), and an area of ectasia of the fundus in the same direction as the tilt (inferonasally). Visual field defects corresponding to the areas of ectasia are frequently seen. The majority of cases are bilateral.
- Usually temporal myopic crescent (although it may also be inferior or annular). It consists of an area where the sclera appears white, due to atrophy of the RPE–Bruch’s membrane–choriocapillaris complex, secondary to the posterior elongation.
- Pale mosaic appearance (tigroid) due to the diffuse attenuation of the RPE with large choroidal vessels visible.

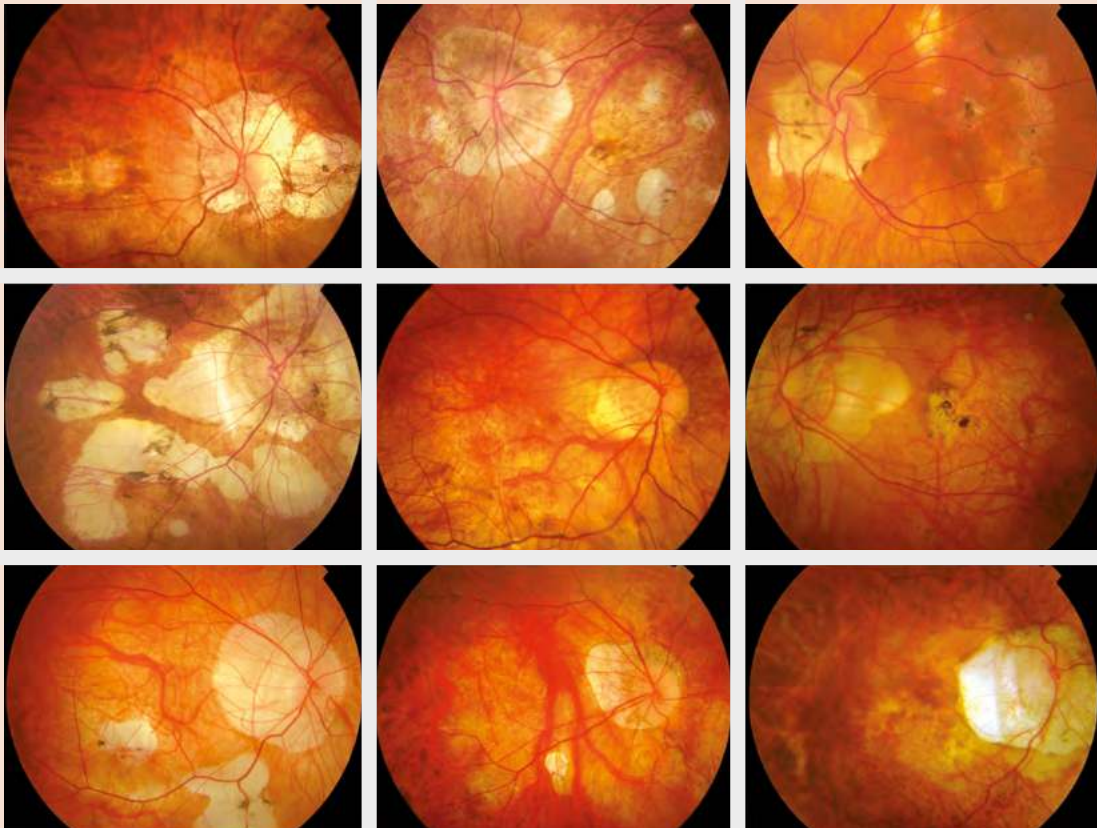

Figure 1. Different images of high myopia (9 to 27 dioptres). Myopia magna has a specific aspect, with a series of anomalies that could affect the patient’s visual function. They are all very characteristic lesions, though not pathognomonic, which could imply tomographic and visual field changes, establishing in many cases a differential diagnosis with glaucoma.

- Peripapillary atrophy that is associated with the presence, progression and location of visual field defects in glaucoma. However, in degenerative myopia, it is the result of the axial elongation of the ocular globe.
- Focal chorioretinal atrophy determined by the visibility of the large choroidal vessels and even the sclera.
- Macular pigment anomalies and a hyperpigmented patch on the macula (Fuchs spot).
- ‘Lacquer cracks’, characterised by narrow, yellow and irregular lines that branch out in a criss-crossing pattern around the posterior pole.
- Subretinal haemorrhages.
- Posterior staphyloma.
- Risk of choroidal neovascularisation (CNV).

D

Differential Diagnosis

- Choroideremia: The differences include nyctalopia, absence of peripapillary changes and preservation of the macula until advanced stages.
- Gyrate atrophy: The differences include early onset of symptoms, lesions that usually have festooned borders and macular preservation until later in life.
- Ocular histoplasmosis: Peripheral atrophy with a risk of CNV. A pigmented ring may separate the optic disc from the peripapillary atrophy. There are rounded choroidal scars (histo spots) scattered throughout the fundus.
- Age-related macular degeneration: While CNV and a macula with a similar appearance may develop, drusen and the characteristics of myopic optic disc will typically be absent.
- Diffuse choroidal atrophy: The differences include diffuse chorioretinal changes instead of perforated lesions such as those in myopia.
- Progressive bifocal chorioretinal atrophy: Early onset and specific macular and nasal retinal atrophic lesions.

E

Systemic Associations

- Stickler syndrome.
- Marfan syndrome.
- Ehlers-Danlos syndrome.
- Pierre-Robin syndrome.
- Down syndrome.

Clinical Correlation with Diagnosis

- Up to 13.2% of eyes with high myopia develop significant defects in the visual field.
- Observing the fundus in myopia magna may be difficult because the atrophy reduces the level of contrast.
- One of the most common changes in the progression of these defects is a reduction in photoreceptor density and a loss of sensitivity, although this does not usually result in absolute scotoma. (Fig. 2).
- The chorioretinal changes associated with high myopia can entail tomographic and visual field changes, which often require a differential diagnosis with lesions compatible with glaucoma, either in the diagnosis or during follow-up.

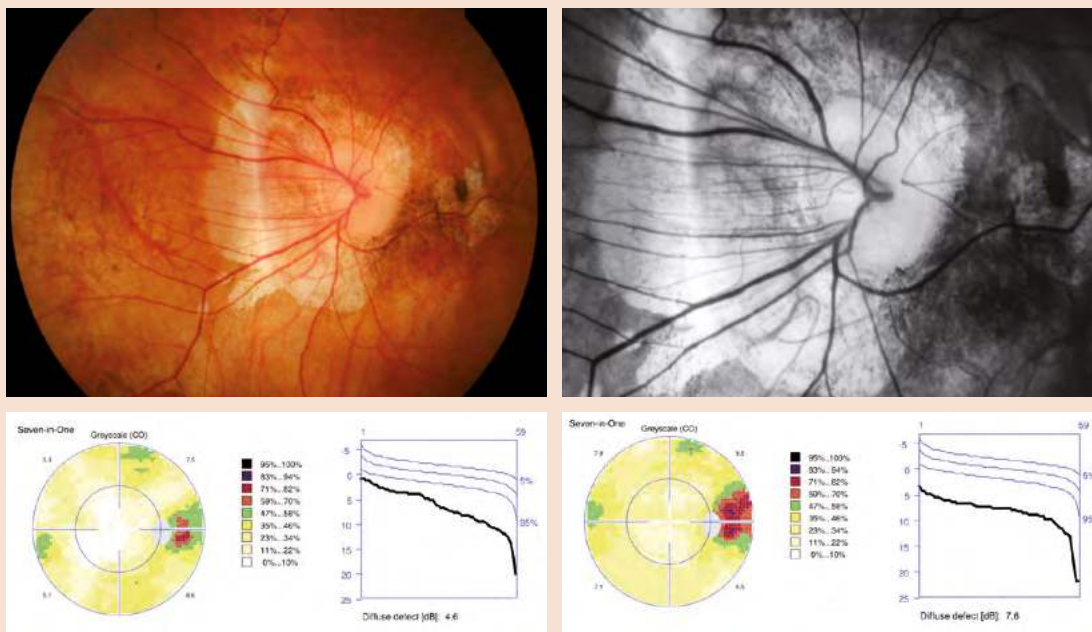


Figure 2. Patient with a degree of myopia of -12 dioptres, where you can observe the evolution of the visual field with gradual loss of sensitivity and an increase of the blind spot.

Myopia-related visual field changes are mostly found in the temporal quadrant, whereas the onset of those associated with glaucoma is more frequent in the nasal quadrants of the visual field.

- The increase of the blind spot is associated with either large optic discs or optic discs with peripapillary atrophy of myopic patients (Fig. 3).
- The relative central scotomas are related to myopic macular degeneration, whereas absolute scotomas are related to macular haemorrhages or Fuchs spots. Cecocentral scotomas are related to peripapillary staphyloma (Fig. 4).

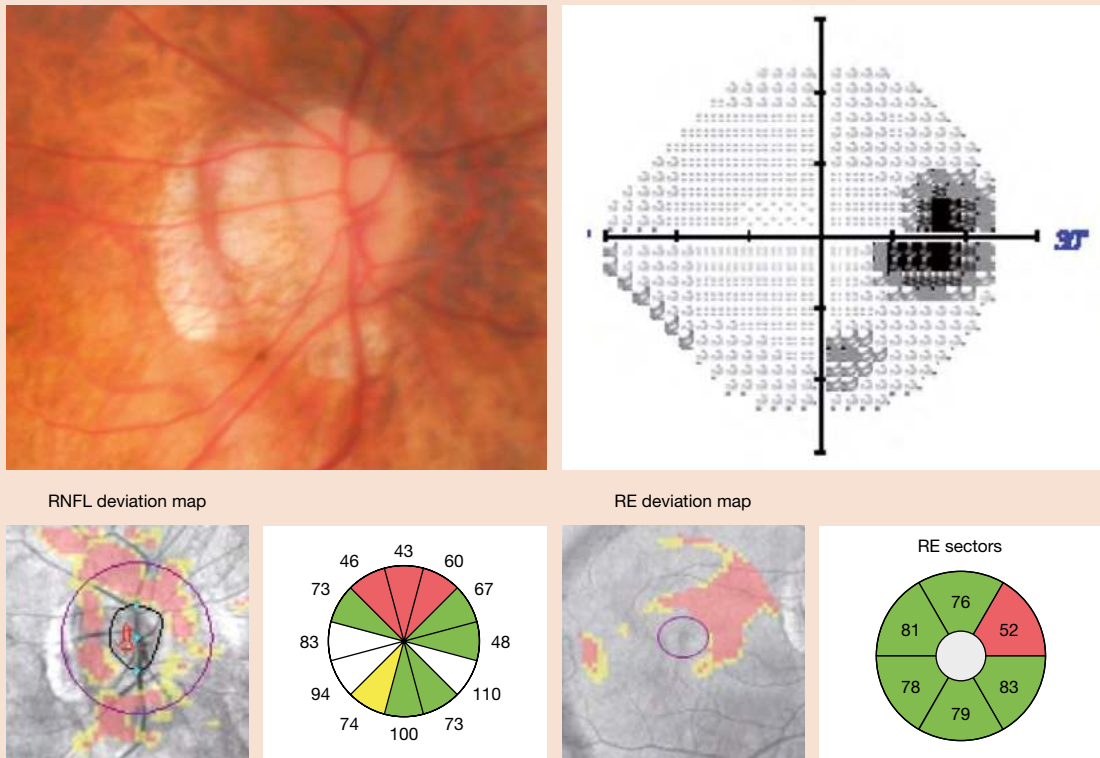


Figure 3. Increased blind spot of a 60-year-old myopic patient (-15 D). Changes in the optical coherence tomography in the optic nerve and the ganglion cells in the same eye.

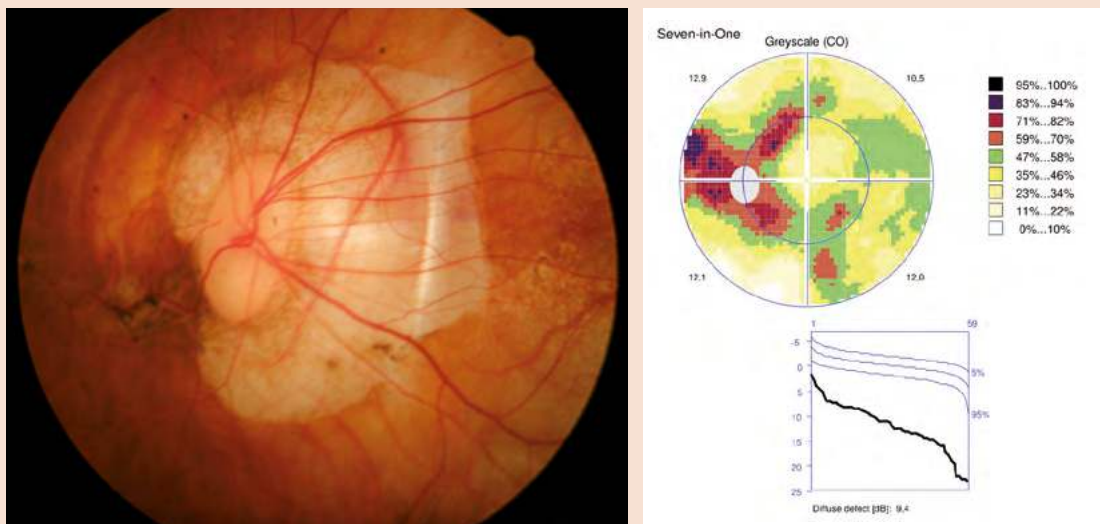


Figure 4. Patient with myopia magna (-14 D) with an increase of the vertical diameter, tilt and peripapillary staphyloma ratio, which gives rise to the incipient centrocecal defect that can be observed in the corresponding visual field.

- Bitemporal quadrantanopsia or hemianopsia may mimic a chiasmal lesion when they are really due to an inferior nasal papillary dispersion, frequent in myopic patients.
- Visual field defects in high myopia are in different locations from the defects usually found in glaucoma. In glaucomatous eyes, anomalies are typically found in the nasal

visual field (the so-called 'nasal step'), and defects in the temporal quadrant normally appear at late stages of the disease. Therefore, visual field alterations in high myopia are not caused by the same mechanisms as in glaucomatous disease.

- In most studies, it has been confirmed that sudden changes in the scleral curvature significantly correlate with the progression of visual field defects. The combination of the elongation and curvature could be the cause of the nerve fibre damage which leads to changes in the visual field. Furthermore, the thinning of the lamina cribrosa plays an important role in the development of visual field defects in patients with high myopia.
- Beyond peripapillary atrophy, an examination with optical coherence tomography (OCT) has made it possible to assess other peripapillary features with high prevalence in degenerative myopia that could easily be overlooked in clinical examination, such as cysts, retinoschisis, choroidal cavitation, paravascular microfolds and lamellar holes, making OCT scans essential in degenerative myopia examinations.
- The new swept-source OCT procedures are capable of scanning the deepest layers of the posterior pole, providing an essential tool to investigate optic nerve pits, thinned lamina cribrosa, elongated dural attachment at posterior scleral canal, and enlargement of retrobulbar subarachnoid spaces. Swept-source OCT therefore enables an in-depth assessment of the visual field defects that occur in high myopia and helps to distinguish them from the pathogenesis of glaucomatous optic neuropathy.

G

Key Points

1

Up to 13.2% of cases of eyes with high myopia develop significant visual field defects.

2

The chorioretinal changes associated with high myopia can lead to tomographic and visual field changes, which often require a differential diagnosis with lesions compatible with glaucoma, either in the diagnosis or during monitoring.

3

It is important to see if there is a correlation between funduscopy and visual field changes in order to establish whether or not there is a structural and functional relationship with myopic changes.

4

Visual field defects in high myopia are often in different locations from the defects usually found in glaucoma.

5

The thinning of the lamina cribrosa also plays an important role in the development of visual field defects in patients with high myopia.

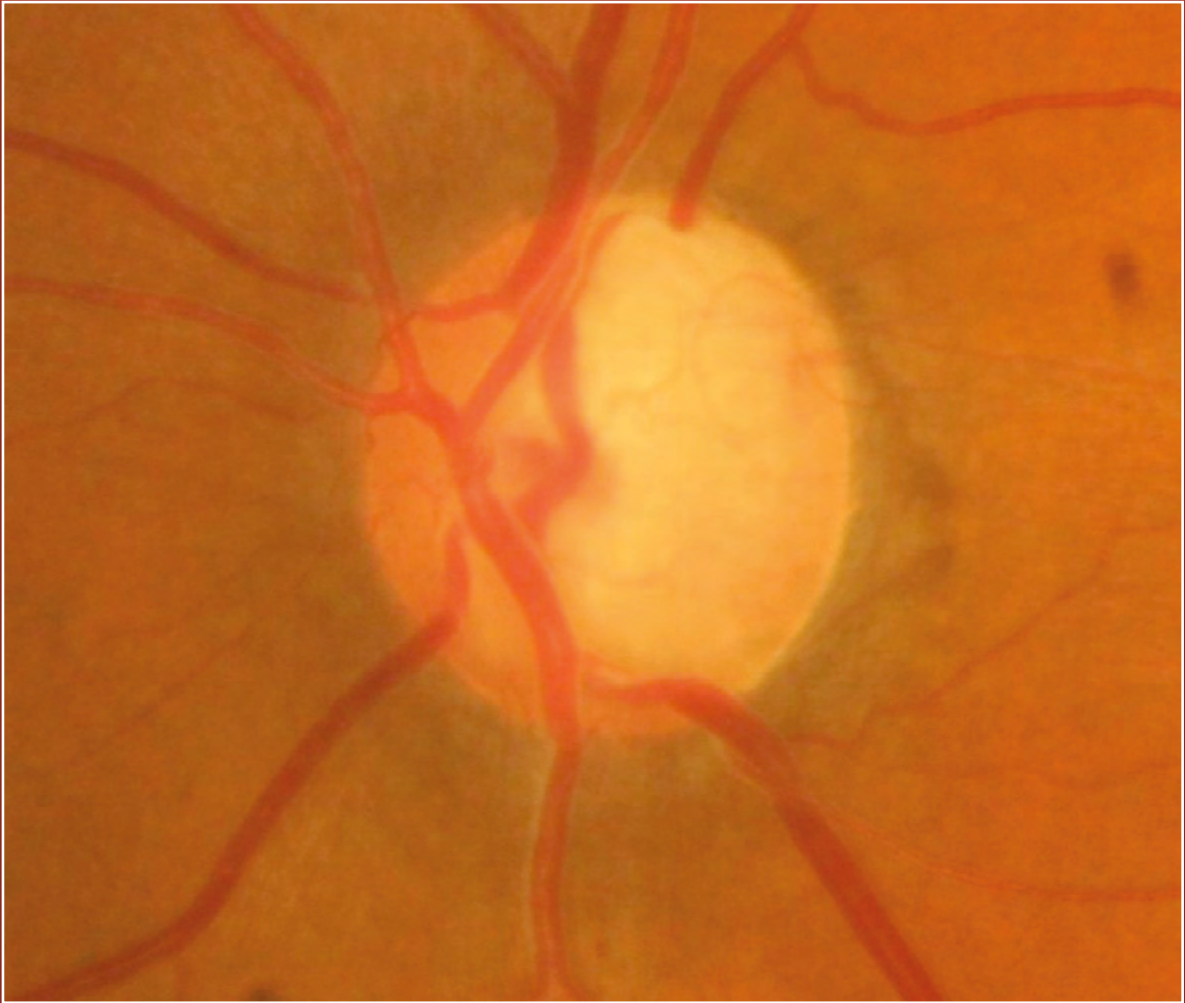
6

OCT has made it possible to assess other highly prevalent peripapillary features in degenerative myopia (cysts, retinoschisis, choroidal cavitation, paravascular microfolds and lamellar holes), making it an essential test in degenerative myopia examinations.



Bibliography

- Bar Dayan Y, Levin A, Morad Y, Grotto I, Ben-David R, Goldberg A, et al. The changing prevalence of myopia in young adults: a 13-year series of population-based prevalence surveys. *Invest Ophthalmol Vis Sci.* 2005;46(8):2760-5.
- Hepei L, Mingkun X, Li W, Jin W. Assessment of BicC family RNA binding protein 1 and Ras protein specific guanine nucleotide releasing factor 1 as candidate genes for high myopia: a case-control study. *Indian J Ophthalmol.* 2017;65(10):926-30.
- Jacobi FK, Zrenner E, Broghammer M, Pusch CM. A genetic perspective on myopia. *Cell Mol Life Sci.* 2005;62(7-8):800-8.
- Kempen JH, Mitchell P, Lee KE, Tielsch JM, Broman AT, Taylor HR, et al.; Eye Diseases Prevalence Research Group. The prevalence of refractive errors among adults in the United States, Western Europe, and Australia. *Arch Ophthalmol.* 2004;122(4):495-505.
- Menezo JL, Güell JL. Corrección quirúrgica de la alta miopía. Barcelona: Espaxs; 2001.
- Muñoz-Negrete FJ, Rebolleda G, Díaz Llopis M. Tomografía de coherencia óptica. Madrid: MacLine; 2011.
- Ng DS, Cheung CY, Luk FO, Mohamed S, Brelen ME, Yam JC, et al. Advances of optical coherence tomography in myopia and pathologic myopia. *Eye (Lond).* 2016;30(7):901-16.
- Ohno-Matsui K, Shimada N, Yasuzumi K, Hayashi K, Yoshida T, Kojima A, et al. Long-term development of significant visual field defects in highly myopic eyes. *Am J Ophthalmol.* 2011;152(2):256-65.e1.
- Pascolini D, Mariotti SP. Global estimates of visual impairment: 2010. *Br J Ophthalmol.* 2012;96(5):614-8.
- Rebolleda G, Díez-Álvarez L, Casado A, Sánchez-Sánchez C, De Dompablo E, González-López JJ, et al. OCT: new perspectives in neuro-ophthalmology. *Saudi J Ophthalmol.* 2015;29(1):9-25.
- Rebolleda G, Muñoz-Negrete FJ. *Protocolos en Neuro-oftalmología.* Madrid: MacLine; 2010.
- Saw SM. How blinding is pathological myopia? *Br J Ophthalmol.* 2006;90(5):525-6.
- Saw SM, Gazzard G, Shih-Yen EC, Chua WH. Myopia and associated pathological complications. *Ophthalmic Physiol Opt.* 2005;25(5):381-91.
- Vitale S, Sperduto RD, Ferris FL 3rd. Increased prevalence of myopia in the United States between 1971-1972 and 1999-2004. *Arch Ophthalmol.* 2009;127(12):1632-9.
- Wojciechowski R. Nature and nurture: the complex genetics of myopia and refractive error. *Clin Genet.* 2011;79(4):301-20.
- Wood EH, Powers MA, Sanislo SR, Gaynon MW. Regarding 'Advances of optical coherence tomography in myopia and pathologic myopia'. *Eye (Lond).* 2017;31(7):1114-5.



Acquired Neurological Defects: Vascular

Gema Rebolleda Fernández
Marta Mármol Díaz
María Isabel Canut Jordana

8

A

Definition

Non-arteritic anterior ischemic optic neuropathy (NAION) is the most frequent cause of optic neuropathy in people over the age of 50, typically characterised by a sudden, painless loss of vision and/or visual field in one eye with optic disc oedema, followed 6 to 8 weeks later by optic atrophy.

B

Etiopathogenesis and Prevalence

There are two types of AION: arteritic (AAION) and non-arteritic (NAION). The most common type is the non-arteritic variant, with an incidence that ranges from 0.54/100000 for the general population to 2-10/100000 in patients over the age of 50. The arteritic type is due to a condition known as giant cell arteritis, and the therapy focuses on the underlying systemic vasculitis. However, the pathogenesis of NAION is still controversial, although it is linked to a hypoperfusion of the optic nerve head linked to predisposing vascular factors.

C

Classification of Non-Arteritic Anterior Ischemic Optic Neuropathy

It is classified according to its clinical presentation: typical, characterised by an acute, painless, monocular loss of vision or visual field in patients older than 45, with optic disc oedema followed 6 to 8 weeks later by pallor of a variable degree; and atypical, when the clinical features do not coincide with those described.

If optic disc oedema is present, a distinction is made between the anterior variant (associated with disc oedema - AION) and the ischemic variant without oedema (posterior ION), which is less frequent and atypical and requires an exhaustive diagnosis protocol to be followed.

D

Clinical Signs

a) NAION:

- A sudden painless monocular loss of vision or visual field and ipsilateral relative afferent pupillary defect.
- Diffuse or sectorial papillary oedema, with optic disc or peripapillary flame-shaped haemorrhages, which subside spontaneously and progressively to give way to a secondary optic atrophy within an average of two months (Figs. 1, 2, 3 and 4 B).
- Although disc excavation usually increases after resolution of the oedema, the increase is clinically overlooked, as it is less evident than when it is arteritic.
- The most frequent visual field defects are inferonasal arcuate defects, followed by inferior altitudinal ones, and may sometimes lead to confusion with glaucomatous optic neuropathy. The patient's clinical history, the pallor of the neuroretinal rim and the absence of notches in the NAION help to establish the differential diagnosis between the two entities (Fig. 1).

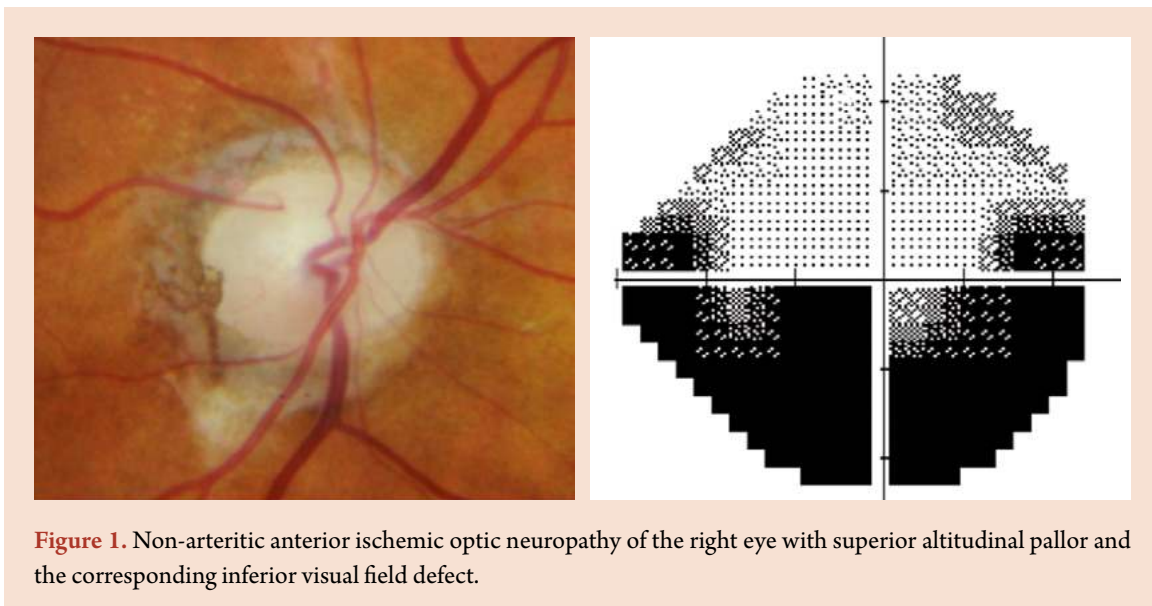


Figure 1. Non-arteritic anterior ischemic optic neuropathy of the right eye with superior altitudinal pallor and the corresponding inferior visual field defect.

- A peripapillary examination using conventional optical coherence tomography (OCT) makes it possible to quantify the progressive reduction of the optic disc oedema (Fig. 2).
- However, a macular OCT scan helps to assess the associated nerve damage earlier (Fig. 2) and identify whether or not it is associated with macular oedema (present in about 15% of cases) (Fig. 3).
- An examination with OCTA makes it possible to identify and quantify the associated loss of optic disc perfusion at an acute stage (Fig. 4 A) and the progressive loss until the optic atrophy stage (Fig. 4 B).

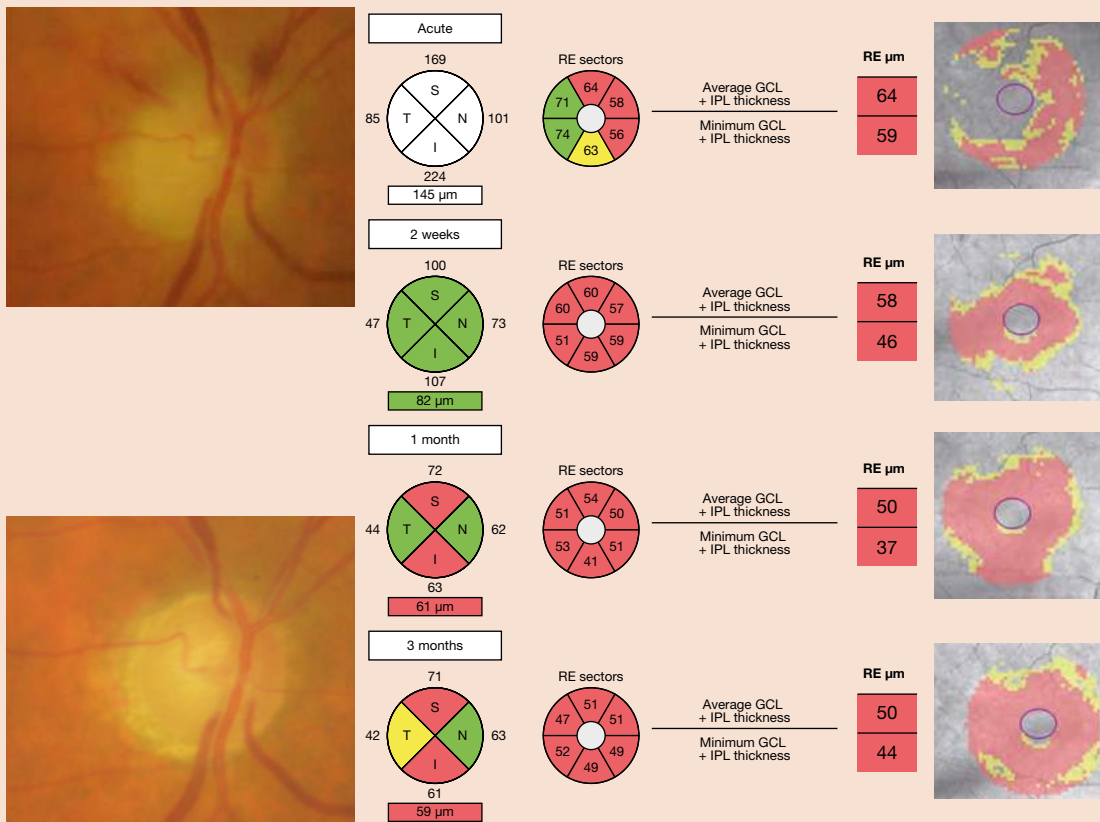


Figure 2. Comparison of peripapillary and macular examinations using optical coherence tomography from the acute stage to the secondary optic atrophy. The nerve damage at macular level that is already evident at the acute stage is not detected until one month later in the peripapillary examination.

GCL: ganglion cell layer; I: inferior; IPL: inner plexiform layer; N: nasal; RE: right eye; S: superior; T: temporal.


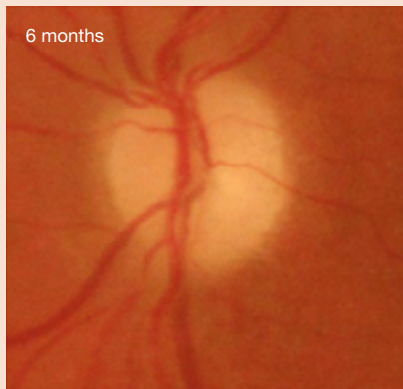
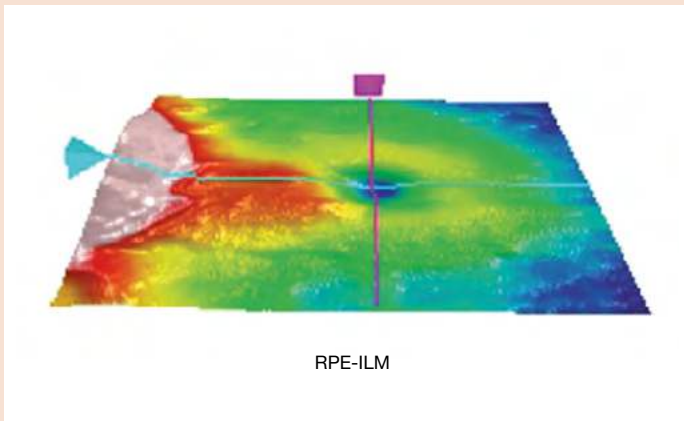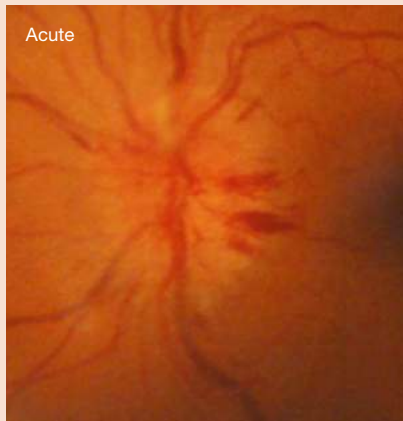


Figure 3. A macular scan using optical coherence tomography reveals the presence of a macular oedema that is not clinically visible at the acute stage, connected to the temporal peripapillary oedema, which is resolved in parallel to the disc oedema (diffuse papillary atrophy).

ILM: internal limiting membrane; RPE: retinal pigment epithelium.

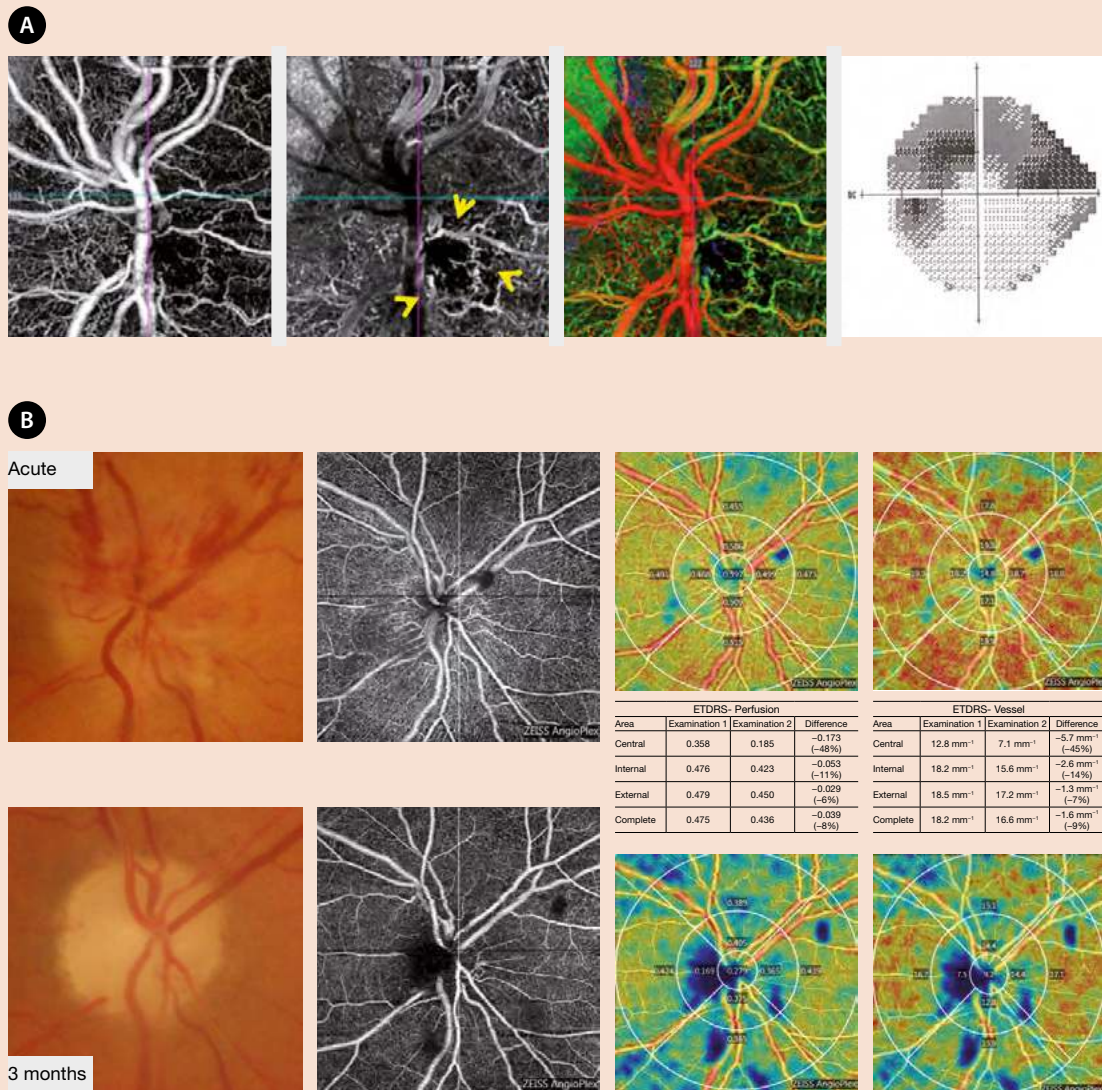


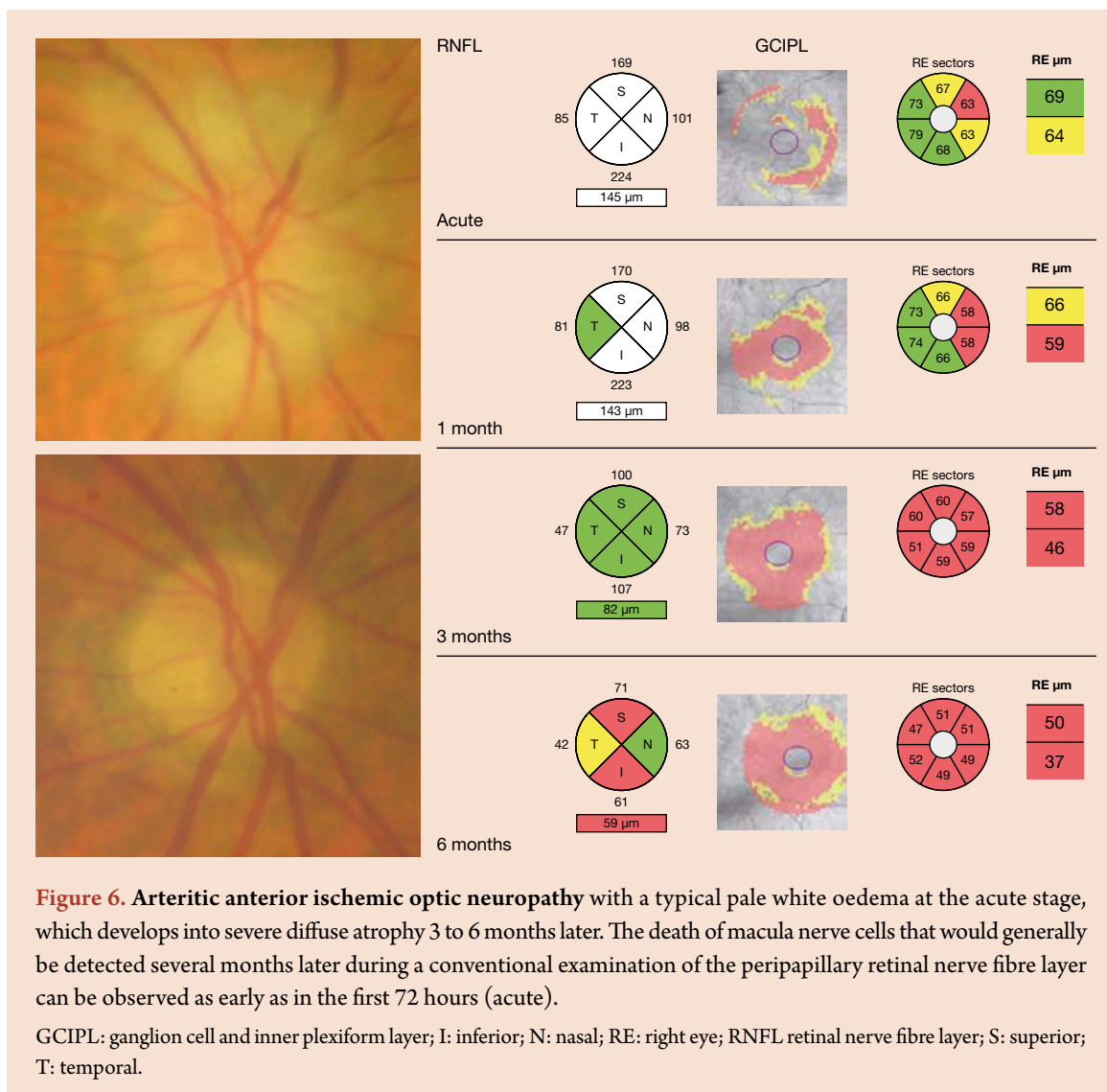
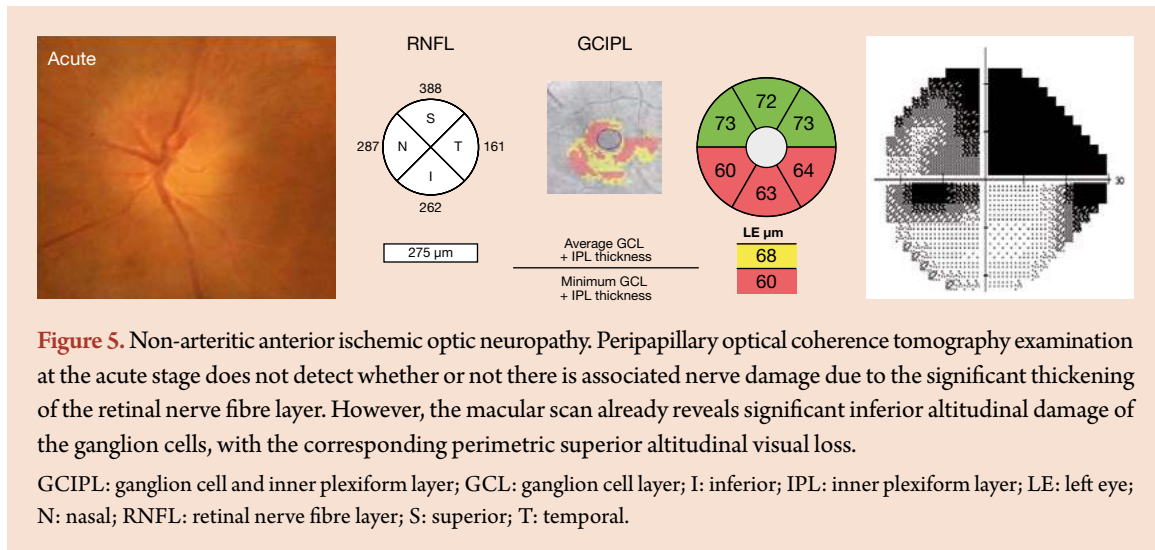
Figure 4. A. Optical coherence tomography angiography (OCTA) after non-arteritic anterior ischemic optic neuropathy, where a severe reduction of the inferotemporal peripapillary perfusion and the corresponding perimetric defect can be observed. **B.** The diffuse loss of vessels and perfusion can be seen (the blue areas correspond to the areas of lower risk/vascular density) using AngioPlex® (CIRRUS™ OCT) from the acute stage to optic atrophy (three months later).

ETDRS: Early Treatment Diabetic Retinopathy Study.

b) AAION:

- More specific general associated symptomatology: jaw claudication and recent cephalaea.
- Previous episodes of amaurosis fugax or diplopia.
- More severe loss of vision and visual field than the arteritic variant.
- Pale, 'chalk-white' oedema.
- Occlusion of the cilioretinal arteries.
- Like NAION (Fig. 5), with OCT the damage can be detected earlier by examining the macula nerves than by examining the peripapillary retinal nerve fibre layer

(RNFL). The damage is greater and appears earlier than in the non-arteritic type (Fig. 6).



- A characteristic aspect is the secondary increase of the optic disc excavation following the resolution of the oedema (Fig. 7). A feature that differentiates it from glaucoma, apart from the clinical history, is that the arteritic excavation is not associated with notches (focal thinning of the neuroretinal rim).

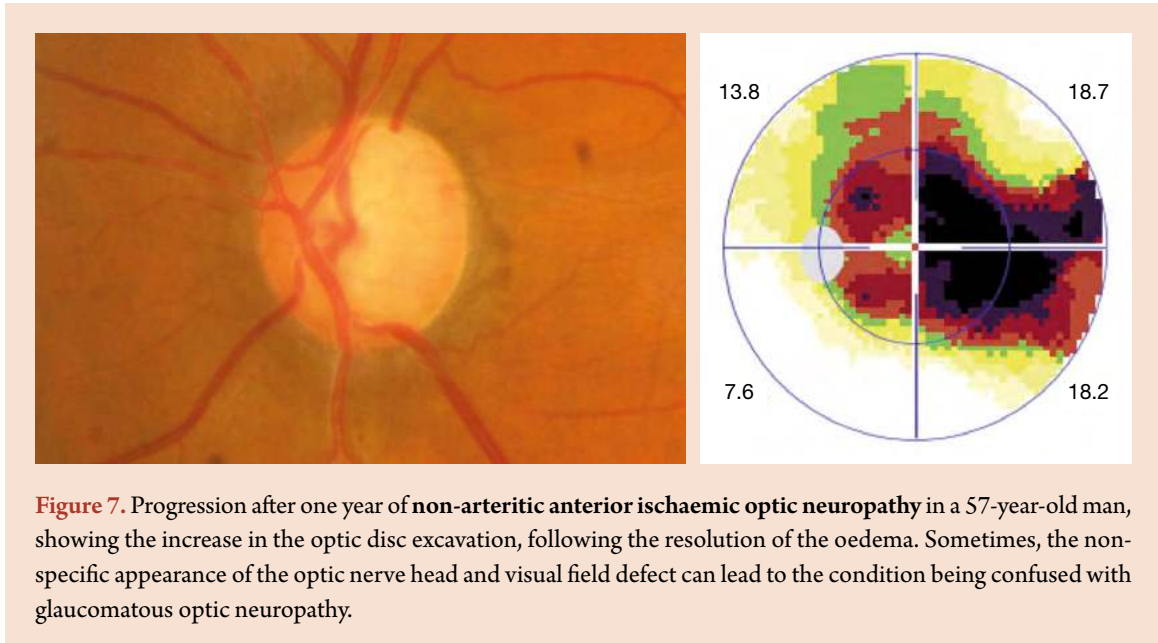


Figure 7. Progression after one year of **non-arteritic anterior ischaemic optic neuropathy** in a 57-year-old man, showing the increase in the optic disc excavation, following the resolution of the oedema. Sometimes, the non-specific appearance of the optic nerve head and visual field defect can lead to the condition being confused with glaucomatous optic neuropathy.

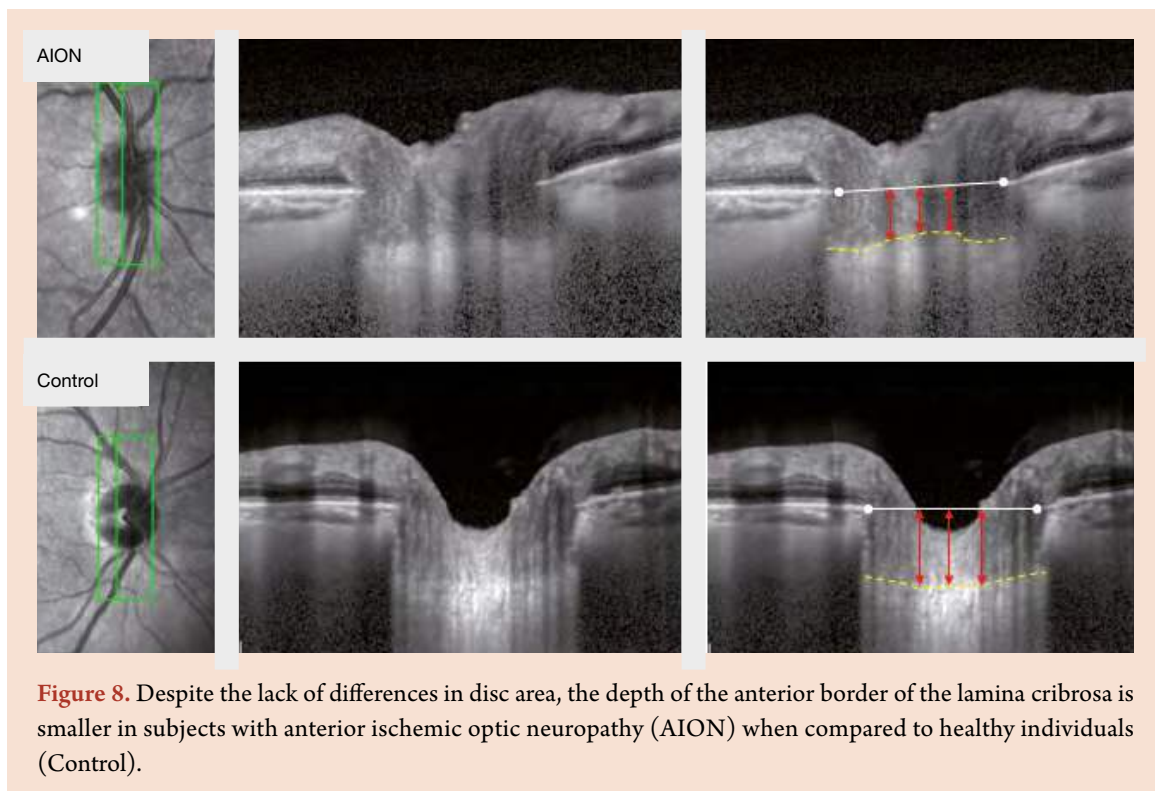
E

Differential Diagnosis

- It is essential to always rule out the arteritic variant, as deferring the therapy or failing to treat the condition properly could lead to bilateral blindness.
- Other optic neuropathies of an inflammatory or compressive origin.
- Occlusion of the central retinal vein or artery.

Ocular and Systemic Associations

- Systemic:
 - Arterial hypertension (AHT) and arteriosclerosis.
 - Nocturnal hypotension (occasionally due to overtreatment of AHT).
 - Diabetes.
 - Hyperlipidaemia in young people.
 - Sleep apnoea.
 - Vasculitis.
 - Thrombophilia.
- Ocular:
 - Disc at risk. Classically associated with a ‘small optic disc’, but it is now known that, even though the area of the disc is similar to that of healthy control eyes, the lamina cribrosa of eyes affected by AION is displaced to an anterior position (a decrease in an anteroposterior direction), and a thickened choroid is associated with this (compartment syndrome) (Fig. 8).



- Optic nerve drusen. The associated neuropathy can be bilateral, usually in younger subjects with a better visual prognosis (Fig. 9).

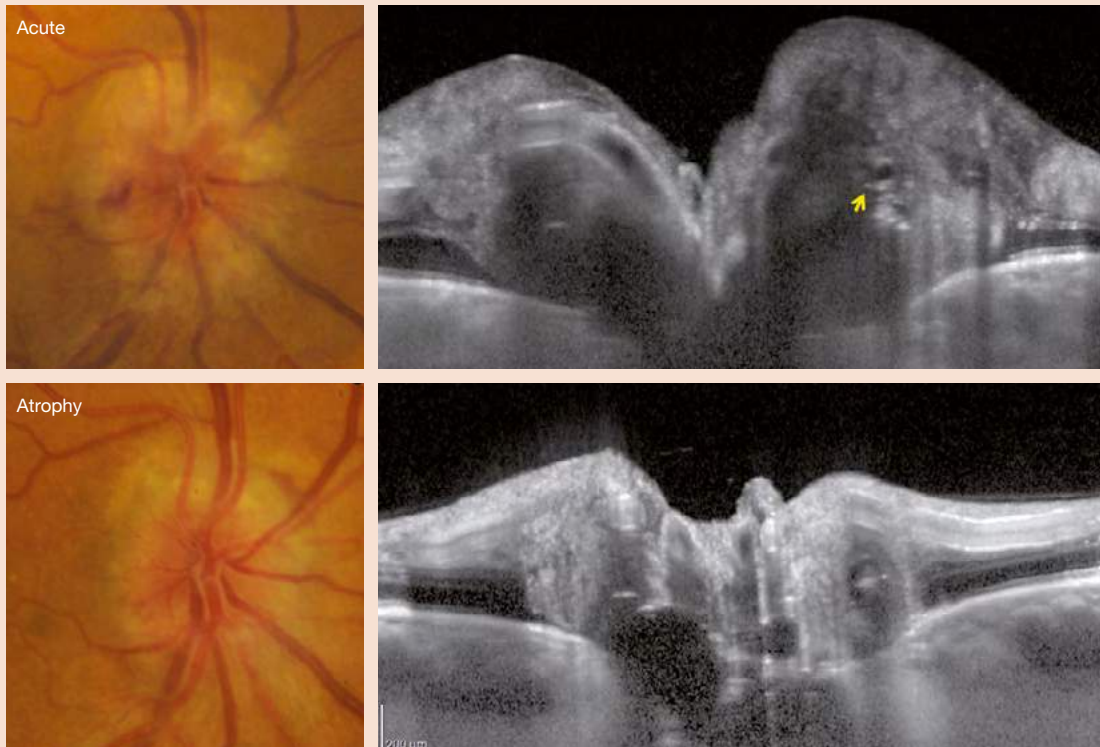


Figure 9. Progression of non-arteritic anterior ischemic optic neuropathy in the right eye of a 37-year-old patient with optic nerve drusen. Although the drusen can be suspected at the acute stage (yellow arrow), they can be seen better after the resolution of the oedema, in both retinography and enhanced depth imaging optical coherence tomography (EDI-OCT) (hyporreflective spaces and multiple hyperreflective bands).

G

Key Points

1

In ION, the perimetric findings are non-specific and the diagnosis cannot be focused in an isolated manner.

2

Vision loss is correlated with damage to the papillomacular bundle.

3

Although there is a secondary increase of optic disc excavation in both entities, it is more evident in the arteritic type. It is therefore one of the differential diagnosis markers of 'non-glaucomatous excavated disc' (Fig. 7).

4

The macular OCT scan of ganglion cells is an early marker of irreversible nerve damage, and it is more useful than the peripapillary examination of the RNFL, which hides the damage caused by the associated peripapillary damage (Figs. 5 and 6).

5

The OCT examination of deep optic disc structures has made it possible to analyse the associated biomechanical changes (retroposition of the lamina cribrosa and enlargement of Bruch's membrane opening at the acute stage, with reversal of changes at the atrophic stage), as well as the predisposing anatomical factors (thickened choroid and anterior displacement of the lamina cribrosa).

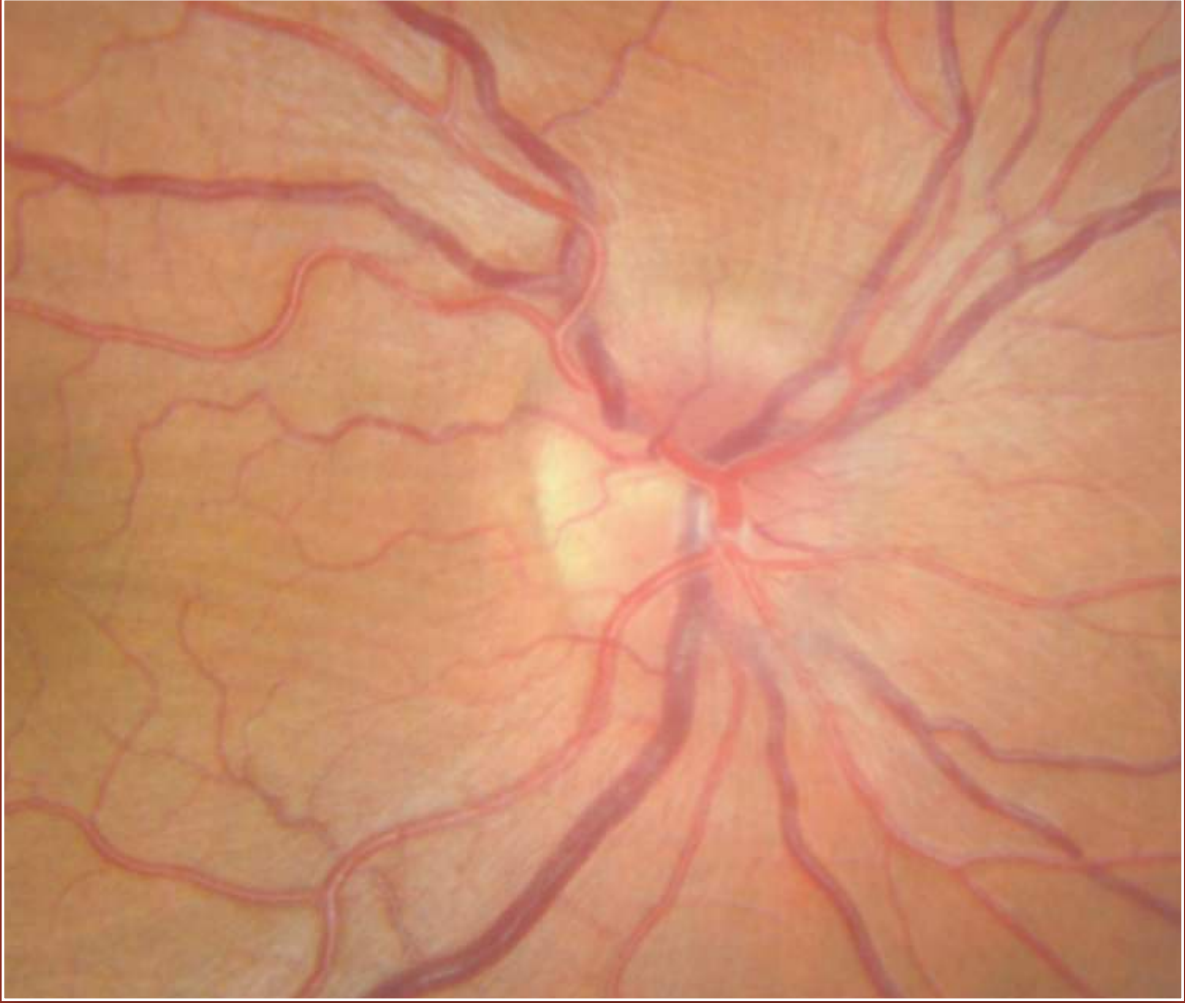
6

OCTA provides the opportunity to study in depth the pathogenesis of this disease and the sequence of the progression of the associated microvascular damage.



Bibliography

- Chen JJ, Leavitt JA, Fang C, Crowson CS, Matteson EL, Warrington KJ. Evaluating the incidence of arteritic ischemic optic neuropathy and other causes of vision loss from giant cell arteritis. *Ophthalmology*. 2016;123(9):1999-2003.
- Contreras I, Rebolleda G, Noval S, Muñoz-Negrete FJ. Optic disc evaluation by optical coherence tomography in nonarteritic anterior ischemic optic neuropathy. *Invest Ophthalmol Vis Sci*. 2007;48(9):4087-92.
- Lee JY, Park A, Oh SY. Prevalence and incidence of non-arteritic anterior ischaemic optic neuropathy in South Korea: a nationwide population-based study. *Br J Ophthalmol*. 2018;102(7):936-41.
- Pérez-Sarriegui A, Muñoz-Negrete FJ, Noval S, De Juan V, Rebolleda G. Automated evaluation of choroidal thickness and minimum rim width thickness in nonarteritic anterior ischemic optic neuropathy. *J Neuroophthalmol*. 2018;38(1):7-12.
- Rebolleda G, Díez-Álvarez L, Casado A, Sánchez-Sánchez C, De Dompablo E, González-López JJ, et al. OCT: New perspectives in neuro-ophthalmology. *Saudi J Ophthalmol*. 2015;29(1):9-25.
- Rebolleda G, Díez-Álvarez L, García-Marín Y, De Juan V, Muñoz-Negrete FJ. Reduction of peripapillary vessel density by optical coherence tomography angiography from the acute to the atrophic stage in non-arteritic anterior ischaemic optic neuropathy. *Ophthalmologica*. 2018;240(4):191-9.
- Rebolleda G, García-Montesinos J, De Dompablo E, Oblanca N, Muñoz-Negrete FJ, González-López JJ. Bruch's membrane opening changes and lamina cribrosa displacement in non-arteritic anterior ischaemic optic neuropathy. *Br J Ophthalmol*. 2017;101(2):143-9.
- Rebolleda G, Muñoz-Negrete FJ. *Protocolos en Neuro-Oftalmología*. 86 Congreso de la Sociedad Española de Oftalmología. Madrid: Sociedad Española de Oftalmología; 2010. p. 38-47.
- Rebolleda G, Pérez-Sarriegui A, Díez-Álvarez L, De Juan V, Muñoz-Negrete FJ. Lamina cribrosa position and Bruch's membrane opening differences between anterior ischemic optic neuropathy and open-angle glaucoma. *Eur J Ophthalmol*. 2019;29(2):202-9.
- Rebolleda G, Sánchez-Sánchez C, González-López JJ, Contreras I, Muñoz-Negrete FJ. Papillomacular bundle and inner retinal thicknesses correlate with visual acuity in nonarteritic anterior ischemic optic neuropathy. *Invest Ophthalmol Vis Sci*. 2015;56(2):682-92.



Acquired Neurological Defects: Compressive

Gema Rebolleda Fernández
Marta Mármol Díaz
Marco Sales Sanz
María Isabel Canut Jordana

9

A

Definition

Among acquired non-glaucomatous optic neuropathies, those of compressive origin, together with ischemic and inherited optic neuropathies, are the most frequent cause of disorders mistakenly labelled as glaucoma, a diagnostic error that has been observed in 20% to 40% of cases.

Any lesion that compresses the optic nerve and/or the visual pathways can cause a visual defect, an acquired increase of the excavation that can be mistaken for glaucoma. Depending on the level, it can also cause variable visual field defects (prechiasm, chiasm, postchiasm), which could lead to a diagnostic confusion with other clinical entities. This is especially relevant, as the onset of compressive neuropathy can occur at any age, affect one or both eyes, and mimic any type of optic neuropathy since, depending on the stage and location of the damage, the optic disc may be normal, oedematous, pale or excavated.

B

Etiopathogenesis and Prevalence

Included among compressive lesions, which can be intrinsic (optic nerve gliomas and meningioma) or extrinsic (thyroid orbitopathy, haemangioma, aneurysms, tumours, etc.), pituitary adenomas account for between 10% and 15% of intracranial tumours and are the most frequent in the sellar region.

It is estimated that fewer than 8% of patients erroneously diagnosed with glaucoma (usually normal-tension glaucoma) have a hidden compressive intracranial lesion. Therefore, neuroimaging tests should be limited to those cases with suspicious signs as mentioned in the differential diagnosis section.



Classification

1. Tumours of the optic disc

- Papillary haemangioma: There are three clinically differentiated types: capillary, cavernous and racemose haemangioma. The diagnosis is simple and is based on fundusoscopic appearance, family history and systemic malformations.
- Optic disc granuloma: These can have an infectious origin or be caused by neurosarcoidosis. Diagnosis is based on clinical appearance, a serological test and neuroimaging study.

2. Tumours of the optic nerve

Benign gliomas in childhood, which are frequently associated with type 1 neurofibromatosis, and optic nerve sheath meningioma account for over 90% of primary tumours of the optic nerve. The clinical presentation is determined by location, size and extension of the tumour. In most cases, the diagnosis is performed by neuroimaging techniques.

- **Optic nerve gliomas:** An inverse correlation between the size of the tumour and both the thickness of the retinal nerve fibre layer (RNFL) and the macular ganglion cell layer has been described. Consequently, the longer the vertical diameter of the tumour, the greater the associated axonal and nerve damage. These parameters are considered risk biomarkers of tumour growth and vision loss (Fig. 1). Based on our experience, RNFL and ganglion cell and inner plexiform layer thicknesses of less than 83 μm and 76 μm have a high diagnostic capacity for eyes with glioma associated with loss of vision.

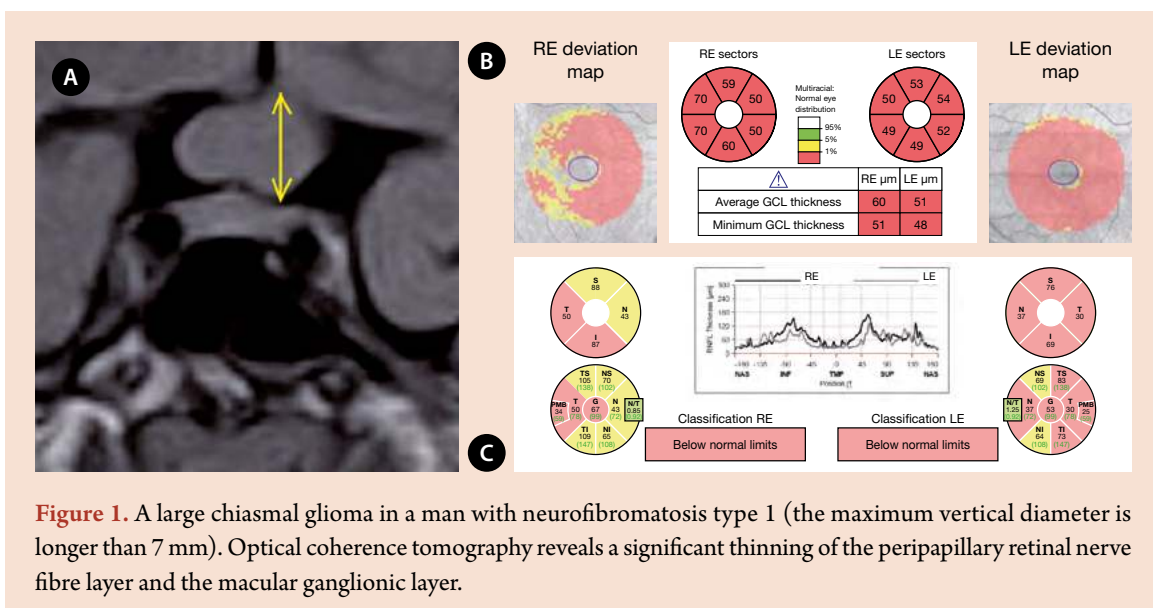
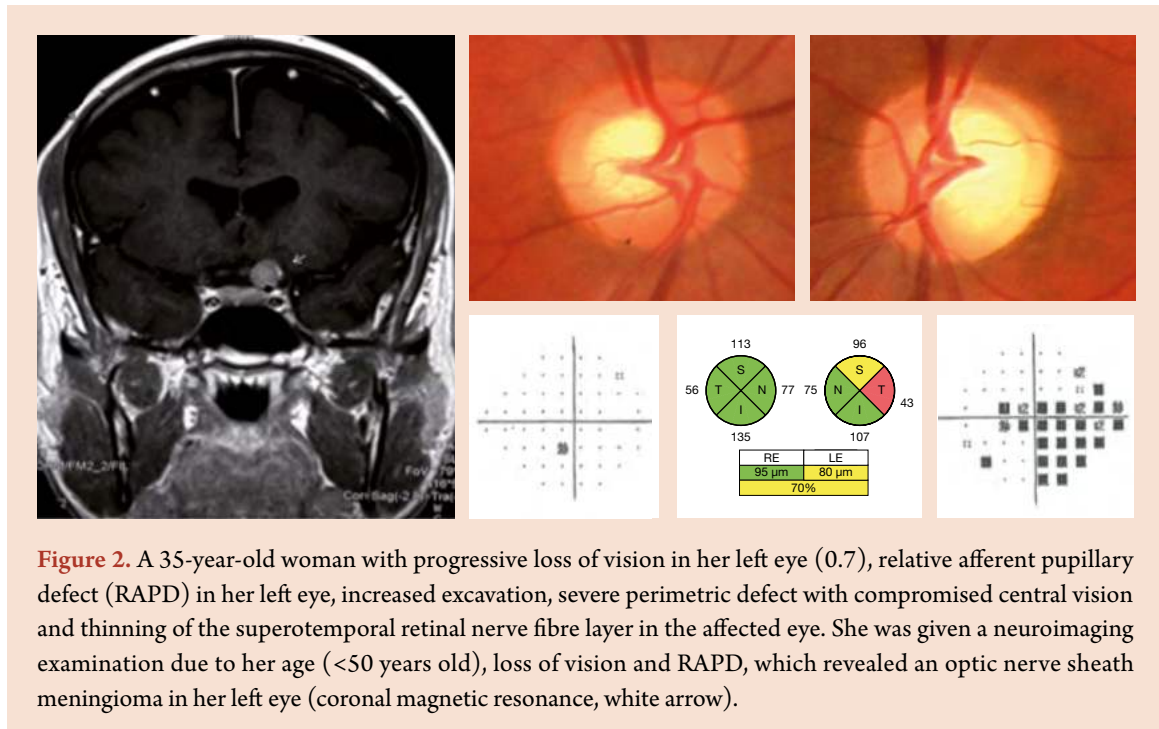


Figure 1. A large chiasmal glioma in a man with neurofibromatosis type 1 (the maximum vertical diameter is longer than 7 mm). Optical coherence tomography reveals a significant thinning of the peripapillary retinal nerve fibre layer and the macular ganglionic layer.

- **Optic nerve sheath meningioma:** These are slow-growing benign tumours, most frequent in middle-aged women. Some patients report transient visual obscurations. The fundusoscopic appearance varies depending on the stage of progression and may present oedema, opticociliary shunts or optic atrophy. The degree of perimetric and neuronal vision loss is highly variable and follows a non-specific pattern (Fig. 2).



- **Other tumours:** Although malignant gliomas in adults are rare, they are very aggressive. Meningoceles and arachnoid cysts do not usually affect vision, but they can be associated with chronic optic disc oedema.

3. Orbital compression

In orbital processes, optic neuropathy is usually preceded or accompanied by proptosis and/or ocular motor dysfunction. The presence of axoplasmic flow stasis within the optic disc area and retinal folds (Figs. 3-5) can often be observed.

- **Inflammatory orbital disease:** This condition comprises diverse aetiologies (idiopathic disease, sarcoidosis, infections, lymphoproliferative syndromes, etc.) and may be located at anterior or apical level, or diffusely. It can also affect different orbital structures (myositis, dacryoadenitis, perineuritis), which result in a very heterogeneous clinical range.
- **Thyroid orbitopathy:** Around 3%-5% of patients suffer optic neuropathy, mainly due to the compression of the optic nerve at the apex level (Fig. 6). Visual loss is usually progressive and asymmetric, and a certain degree of oedema can be found relatively often. Nuclear magnetic resonance (NMR) imaging of the orbit is sometimes chosen to assess the degree of apical crowding.

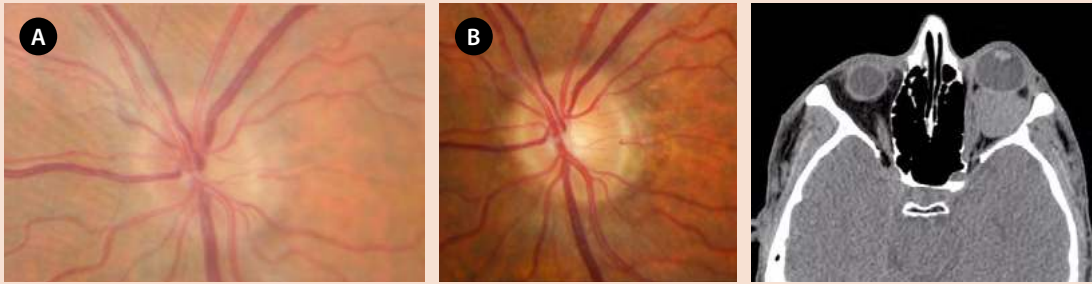


Figure 3. A cavernous haemangioma in the left orbit, causing proptosis, as well as congestion of the optic disc and oblique nasal peripapillary folds (A), with resolution after surgical extirpation (B).

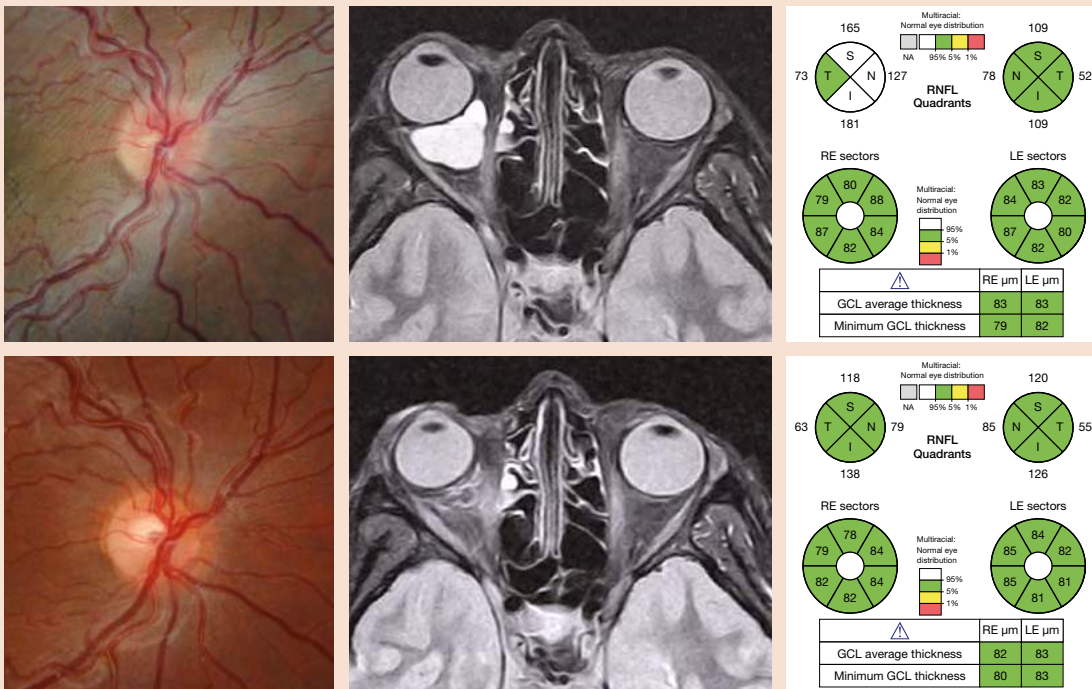


Figure 4. Intraorbital lymphangioma in the right eye. It is associated with right proptosis, congestion of the optic disc and peripapillary folds in the temporal region (top row), which resolve after the extirpation of the tumour (bottom row). The pre-operative optic coherence tomography (OCT) scan of the retinal nerve fibre layer shows the optic disc oedema but does not show whether or not there is any associated axonal damage. In this case, the OCT scan of the macular ganglion cells is normal and is a prognostic indicator of resolution without sequelae, as could be seen in both examinations once the oedema had been resolved after surgery.

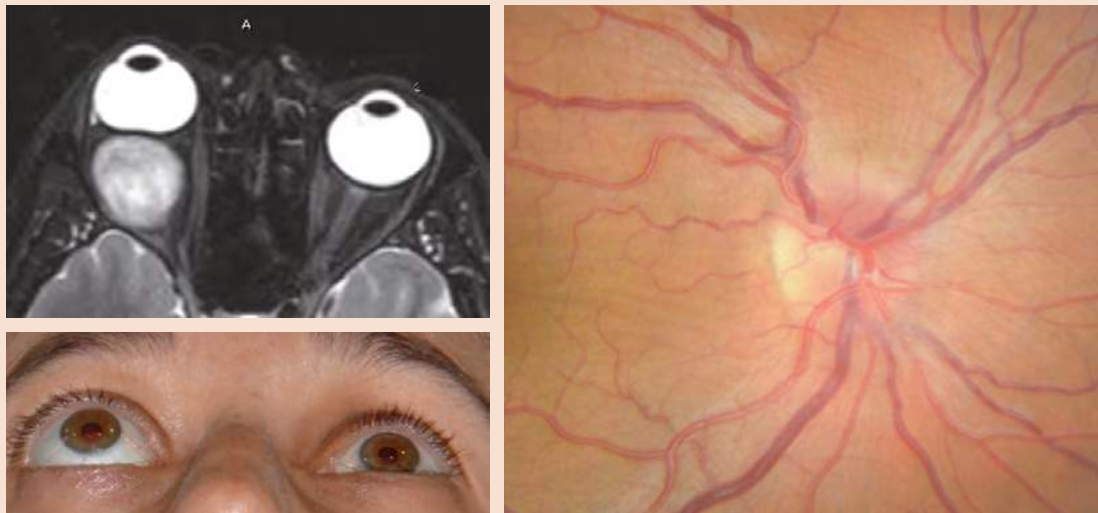


Figure 5. Orbital schwannoma in the right eye. The right proptosis, congestion of the disc and retinal folds are evident.

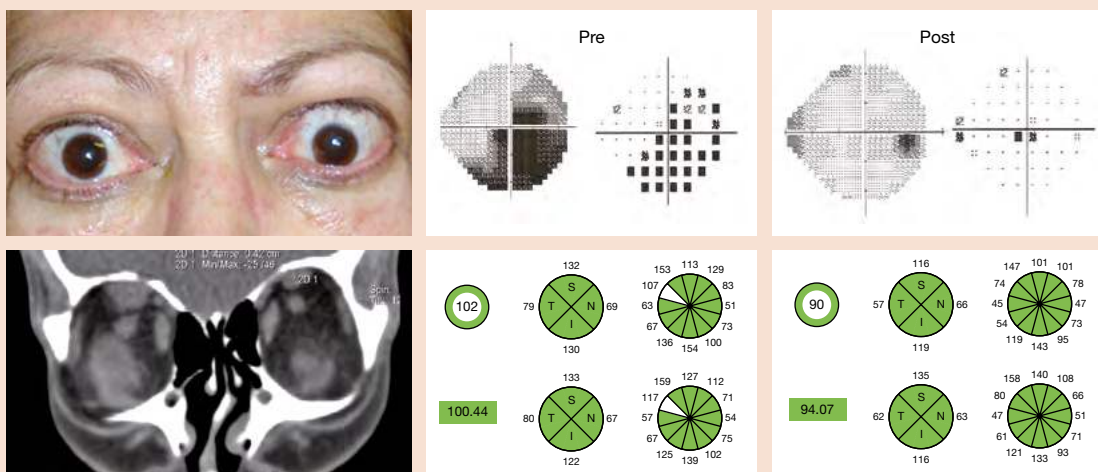


Figure 6. Compressive optic neuropathy in the right eye caused by thyroid orbitopathy, with severe visual field defect. The pre-operative optic coherence tomography scan of the retinal nerve fibre layer was normal, indicating a good prognosis of functional recovery, as seen after the orbital decompression, with substantial improvement of the perimetric defect.

- **Orbital compartment syndrome:** Caused by any event that suddenly increases the orbital volume. The most frequent cause is orbital haemorrhage. Diagnosis is based on clinical history and orbital neuroimaging. Symptoms include acute loss of vision, painful ophthalmoplegia, palpebral oedema and proptosis. Optic disc oedema and venous tortuosity can be seen in the fundus. Urgent decompression is required to prevent irreversible damage.
- **Other orbital lesions:** These include different tumour processes (e.g. cavernous haemangioma (Fig. 3), schwannoma (Fig. 5), rhabdomyosarcoma, etc.), metastasis or orbital vascular lesions (varicose veins, lymphangioma (Fig. 4), arteriovenous malformations).

4. Lesions at the intracranial or intracanalicular level, or behind the orbit

These may be clinically overlooked, as vision loss is usually slow, progressive and painless, with variable ranges and non-specific visual field defects. A less frequent symptom is sudden-onset visual loss, either due to bleeding or acute ischemia, such as in pituitary apoplexy.

D

Clinical Signs

- The compression of the optic nerve in the anterior orbit can cause disc oedema (Figs. 3-5). However, oedema is rare in intracanalicular or intracranial compressive lesions, except if they are associated with intracranial hypertension (Fig. 7).

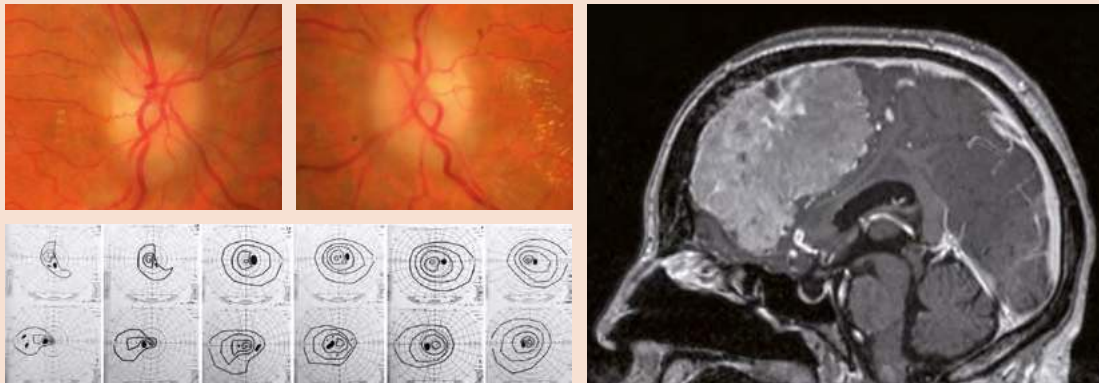


Figure 7. 41-year-old woman with optic disc oedema, cephalaea and progressive vision loss in both eyes (right eye [RE]: 0.35; left eye [LE]: 0.75) caused by a large left intracranial meningioma. Progressive recovery of visual field (initially right homonymous hemianopsia) and vision (RE: 1.0; LE: 0.9) four years after the treatment.

- The presence of optociliary shunts, although they are not exclusive to compressive pathology and may also be seen idiopathically in venous occlusions and glaucoma, makes it advisable to carry out a neuroimaging test (Fig. 8).

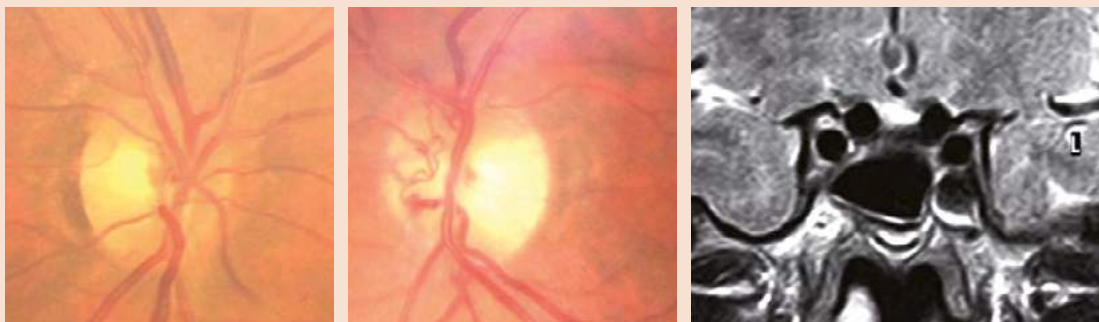


Figure 8. Optociliary shunts in the left eye associated with optic pallor, secondary to progressive compression of the left optic nerve by the artery supraclinoid segment.

- In pregeniculate lesions, a bow-tie or band optic atrophy can be observed.
- The associated perimetric defects will depend on the size, nature and location of the lesion:
 - Prechiasmal defects: These are typically unilateral and cross the vertical midline, respecting the horizontal nasal raphe (nasal step), and may be accompanied by alterations in the fundus of the eye and a relative afferent pupillary defect. When the lesion is located near the chiasma, we can see a bilateral visual field defect (junctional or Traquair scotoma).
 - Chiasmal defects: Although the lesions that compress the chiasma (pituitary adenoma and craniopharyngioma) are typically associated with bitemporal hemianopsia, this pattern is seen in less than half of patients. Asymmetric and even monocular symptoms are not rare (Fig. 9).

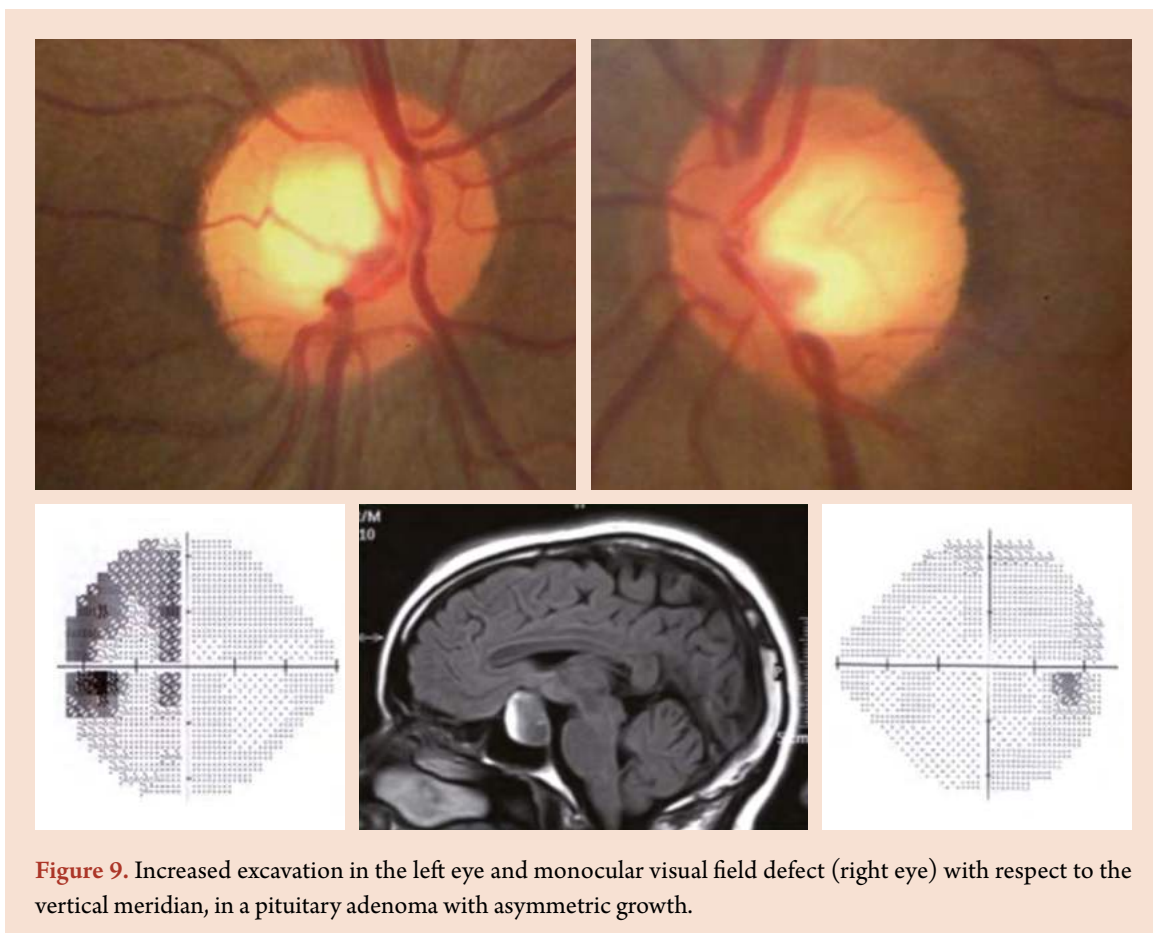


Figure 9. Increased excavation in the left eye and monocular visual field defect (right eye) with respect to the vertical meridian, in a pituitary adenoma with asymmetric growth.

- Postchiasmal defects: The typical defect is a contralateral homonymous hemianopsia, and the closer the lesion is to the occipital lobe, the more congruous it is.
- Defects that mimic a lesion of the optic nerve or tract, depending on whether the chiasma is postfixed (Fig. 10) or prefixed, respectively, can be observed.
- In retrochiasmal lesions, OCT can detect whether transsynaptic degeneration has occurred. In this case, a thinning of the retinal ganglion cells, as well as inadequate perfusion corresponding to the affected side of vision, can be observed (Fig. 11).

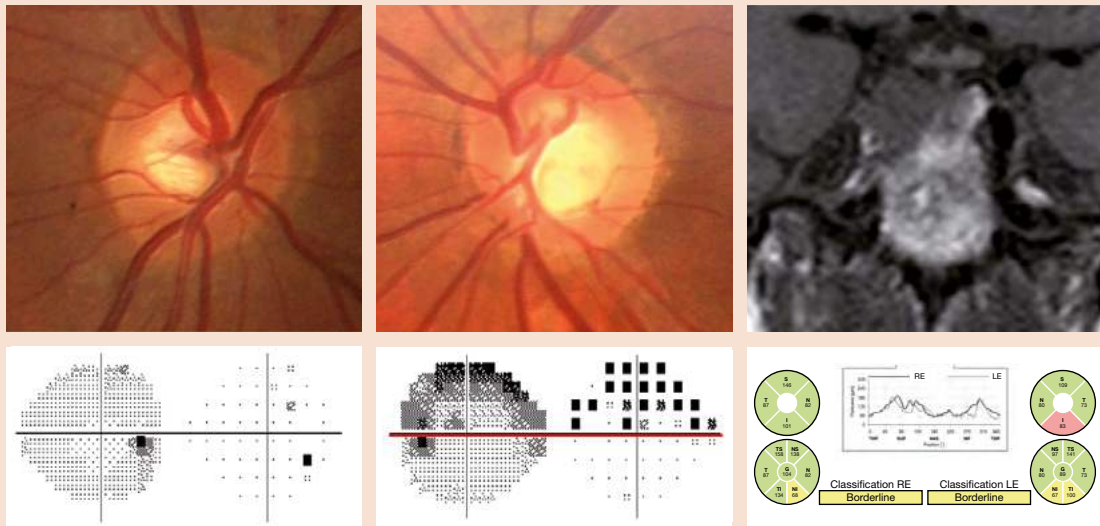


Figure 10. 48-year-old man with a progressive loss of vision in his left eye (0.4), asymmetry in the excavation/disc ratio, and a superior altitudinal defect, which corresponds to the inferior thinning of the retinal nerve fibre layer in the left eye. Although the lesion respects the horizontal meridian, it is located at the pituitary level (pituitary macroadenoma), but the chiasma is postfixed, so the perimetric defect mimics a prechiasmal compression.

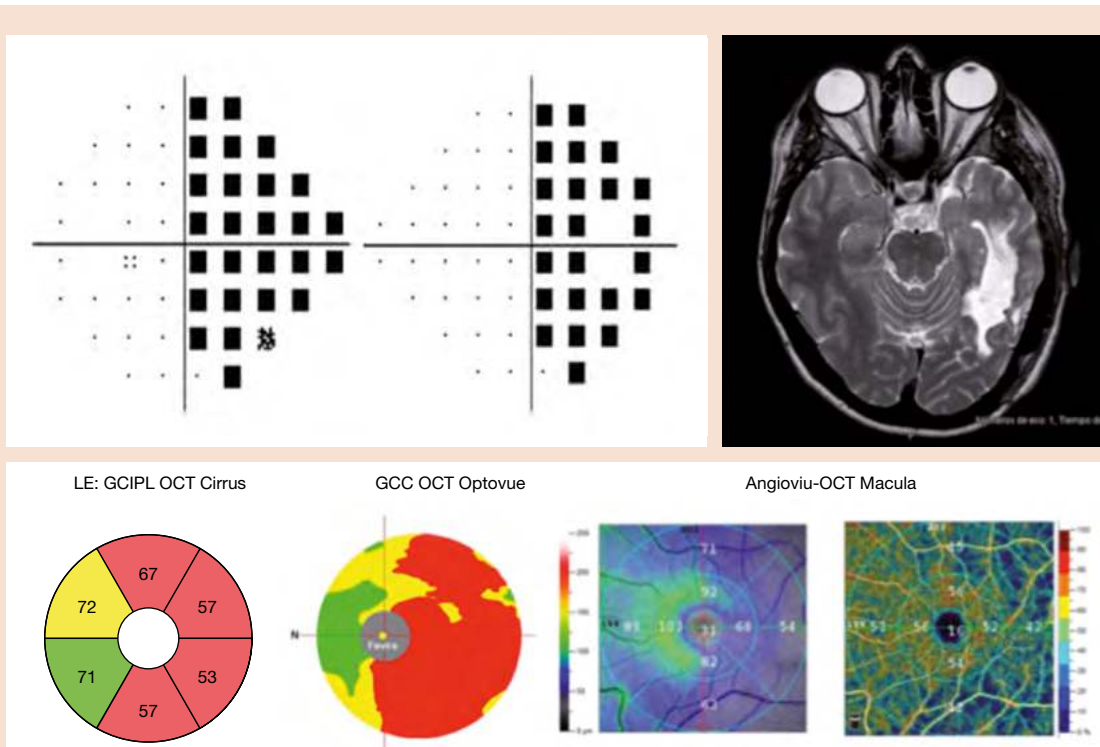


Figure 11. Right homonymous hemianopia after a left temporoparietal stroke. The macular scans of the left eye using OCT CIRRUS™ and Optovue optical coherence tomography show significant thinning of the ganglion cells and perfusion loss in the hemimacula where the ganglion cells reside that project in the affected hemifield.

E

Differentiating Features between Optic Neuropathies of Neurological Origin and those of Glaucomatous Origin

There are several clinical features that point towards compressive origin and make it advisable to perform a neuroimaging test:

- Patient under 50 years of age.
- Visual acuity below 0.5.
- Respect of the vertical meridian in the visual field defect (unilateral or bilateral).
- Predominance of the pallor of the ring above the excavation.
- Severe RAPD or dyschromatopsia, central or cecocentral scotoma and whenever the clinical progression is atypical or there is a discrepancy between the clinical findings and additional tests.

Although these features are very specific to compression, they lack sensitivity: they are only present in half of all cases.

As regards respecting the vertical meridian, a diagnosis tool known as the Neurological Hemifield Test (NHT), which compares 16 points of the left visual hemifield with their right counterparts on the Humphrey deviation plot, has been available since 2011. The numerical total of the difference is used to give a score. When the asymmetry is greater than 30, the risk of the defect being neurological rather than glaucomatous increases substantially (Fig. 12).




Figure 12. Usefulness of the Neurological Hemifield Test (NHT) to differentiate whether the visual field defects are incomplete superior arcuate defects in both eyes of glaucomatous origin or an incomplete right quadrantanopia of neurological origin. The NHT value is 45 in the left eye (sensitivity: 89%; specificity: 72%) and 70 in the right eye (sensitivity: 75%; specificity: 98%), which suggests a neurological origin; in this case, a left temporal stroke.

This test makes it possible to correctly label around 95% of cases, with the majority of misclassifications occurring in binasal defects (Fig. 13).

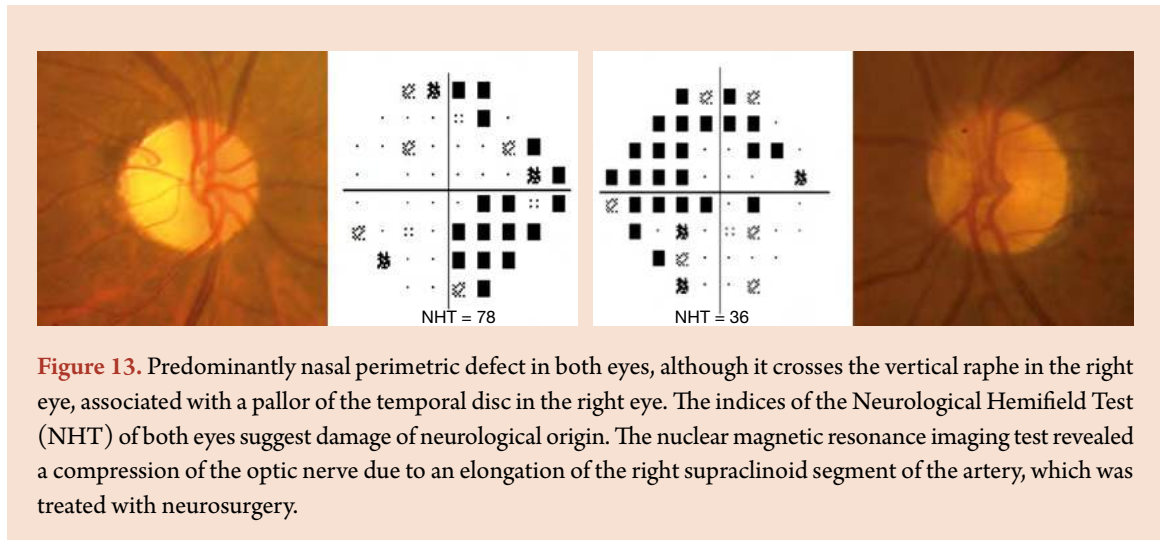
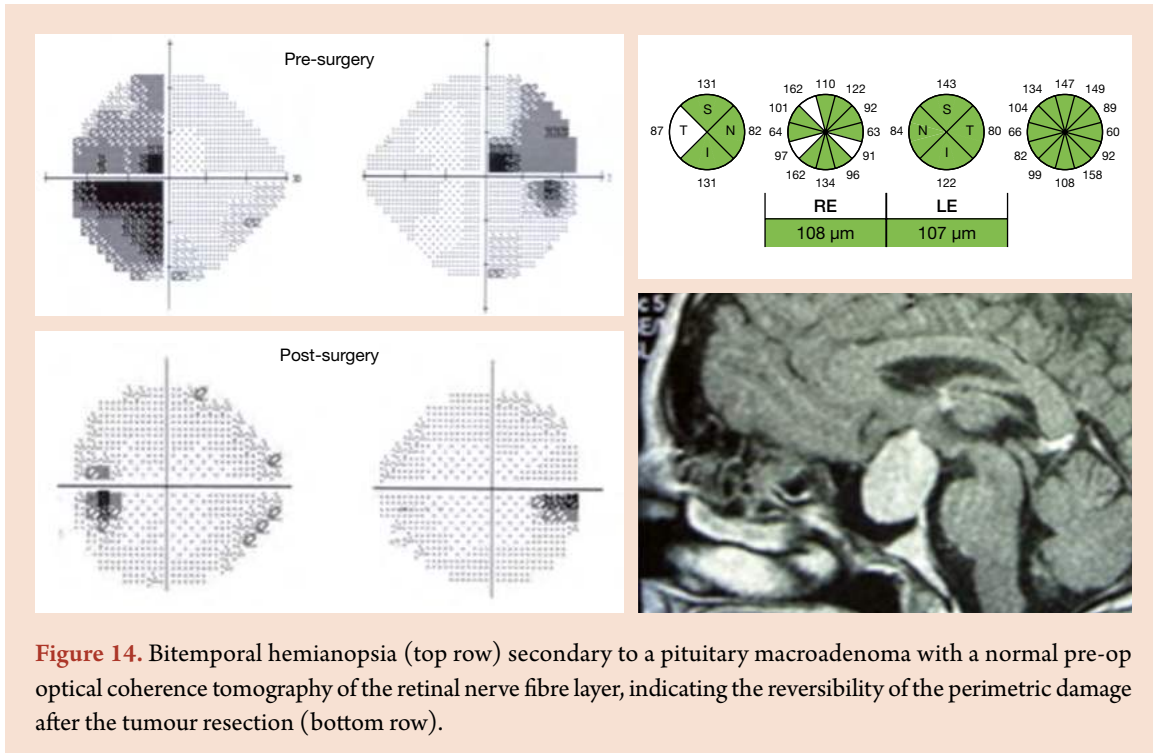


Figure 13. Predominantly nasal perimetric defect in both eyes, although it crosses the vertical raphe in the right eye, associated with a pallor of the temporal disc in the right eye. The indices of the Neurological Hemifield Test (NHT) of both eyes suggest damage of neurological origin. The nuclear magnetic resonance imaging test revealed a compression of the optic nerve due to an elongation of the right supraclinoid segment of the artery, which was treated with neurosurgery.



Prognostic Factors

Unlike campimetry, pre-op OCT has proven to be extremely useful in predicting the degree of irreversible damage associated with these tumours, making it possible to predict the degree of recovery after straightforward surgical procedures for both orbital and intracranial lesions (Figs. 4, 6, 14 and 15).



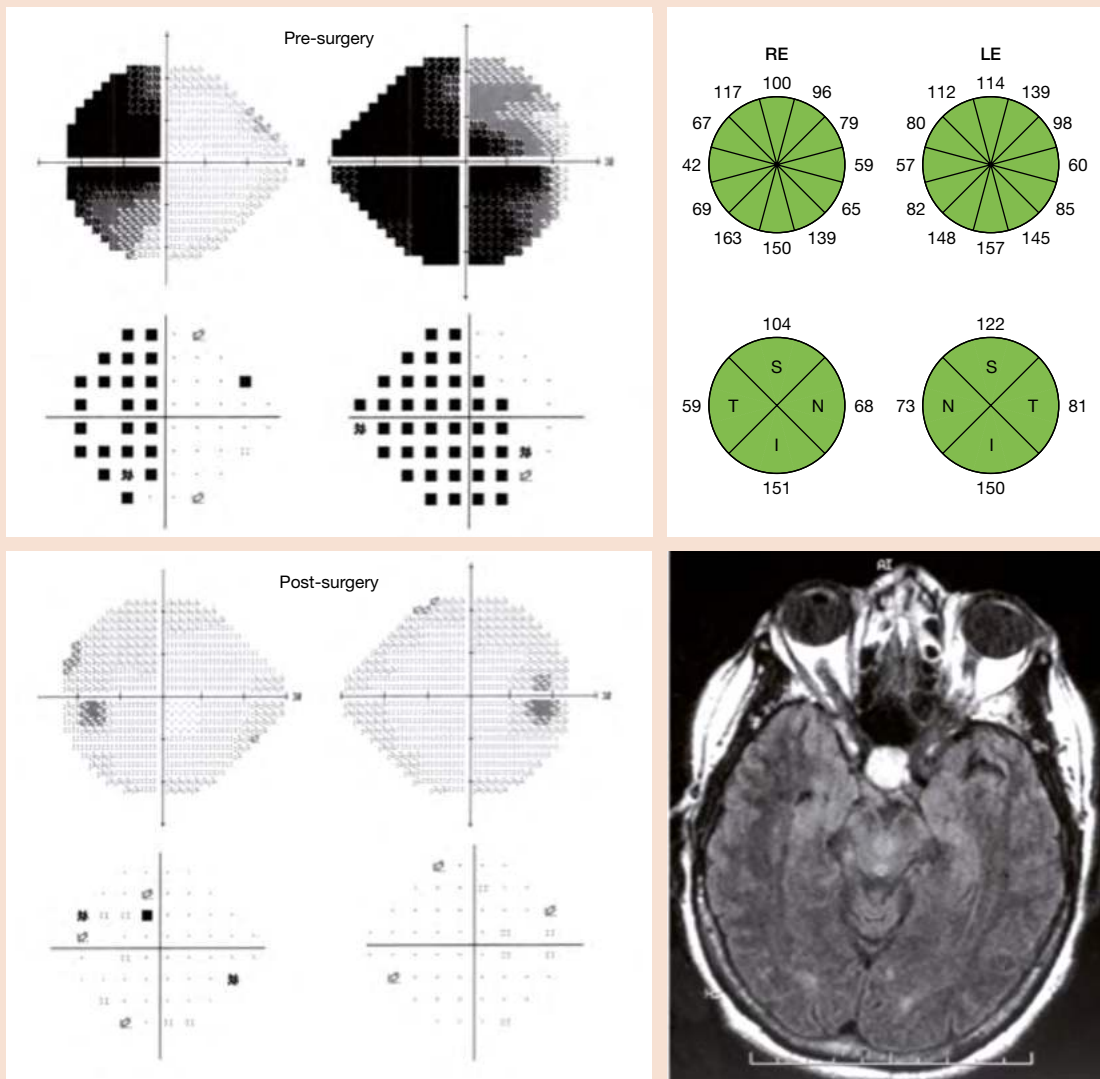


Figure 15. Pre-surgery and post-surgery perimetry of a craniopharyngioma. The presence of a normal pre-surgery optic coherence tomography of the peripapillary retinal nerve fibre layer of both eyes (prognostic biomarker) makes it possible to predict the recovery and disappearance of the visual defect after surgery.

G

Differential Diagnosis

- Optic neuropathy of vascular, inflammatory or infectious origin.
- Neuropathy associated with cancer.
- Glaucoma.
- Central retinal vein occlusion.
- Congenital opticociliary shunts.



Ocular and Systemic Associations

- A papillary haemangioma is usually associated with haemangioma in the central nervous system or is part of Von Hippel-Lindau syndrome.
- A retinal racemose haemangioma can be associated with other brain malformations (Wyburn-Mason syndrome).
- Bilateral or multifocal optic nerve sheath meningioma can be associated with neurofibromatosis type 2.

I

Key Points

1

Compressive optic neuropathy may be monocular or binocular and can adopt any clinical pattern, appear at any age, in a normal manner, with pallor, oedema or papillary atrophy, mimicking any optic neuropathy, including glaucoma, and should therefore always be included in the differential diagnosis.

2

Optic disc oedema that persists longer than two or three months, as well as retinal folds, proptosis or strabismus, require an orbital neuroimaging study.

3

A thorough overall examination of the patient and a high degree of suspicion, coupled with the corresponding imaging tests, are key elements in the diagnosis.

4

An OCT scan of the RNFL and ganglions is very useful when assessing induced axonal and nerve damage. Furthermore, it is a prognostic marker in compressive lesions located at both orbital (Figs. 4 and 6) and intracranial (Figs. 14 and 15) levels. In the case of optic disc oedema, it is the ganglion examination at macular level that determines the prognostic value, as it is not contaminated by the thickening of the peripapillary RNFL (Fig. 4).

5

OCT has shown that a high percentage of patients with retrochiasmal lesions develop a transsynaptic degeneration that results in thinning of the retinal ganglion cells, as well as inadequate perfusion corresponding to the affected visual side (Fig. 11).



Bibliography

- Avery Liu GT, Fisher MJ, Quinn GE, Belasco JB, Phillips PC, et al. Retinal nerve fiber layer thickness in children with optic pathway gliomas. *Am J Ophthalmol.* 2011; 151(3):542-9.e2.
- Avery A, Mansoor A, Idrees R, Trimboli-Heidler C, Ishikawa H, Packer RJ, et al. Optic pathway glioma volume predicts retinal axon degeneration in neurofibromatosis type 1. *Neurology.* 2016;87(23):2403-7.
- Boland MV, McCoy AN, Quigley HA, Miller NR, Subramanian PS, Ramulu PY, et al. Evaluation of an algorithm for detecting visual field defects due to chiasmal and post-chiasmal lesions: the neurological hemifield test. *Invest Ophthalmol Vis Sci.* 2011; 52(11):7959-65.
- Danesh-Meyer HV, Papchenko T, Savino PJ, Law A, Evans J, Gamble GD. In vivo retinal nerve fiber layer thickness measured by optical coherence tomography predicts visual recovery after surgery for parachiasmal tumors. *Invest Ophthalmol Vis Sci.* 2008; 49(5):1879-85.
- Dias DT, Ushida M, Battistella R, Dorairaj S, Prata TS. Neurophthalmological conditions mimicking glaucomatous optic neuropathy: analysis of the most common causes of misdiagnosis. *BMC Ophthalmol.* 2017;17(1):2.
- Drummond SR, Weir C. Chiasmal compression misdiagnosed as normal-tension glaucoma: can we avoid the pitfalls? *Int Ophthalmol.* 2010;30(2):215-9.
- Fard MA, Fakhree S, Eshraghi B. Correlation of optical coherence tomography parameters with clinical and radiological progression in patients with symptomatic optic pathway gliomas. *Graefes Arch Clin Exp Ophthalmol.* 2013;251(10):2429-36.
- Forte R, Bonavolonta P, Vassallo P. Evaluation of retinal nerve fiber layer with optic nerve tracking optical coherence tomography in thyroid-associated orbitopathy. *Ophthalmologica.* 2010;224(2):116-21.
- Greenfield DS, Siatkowski RM, Glaser JS, Schatz NJ, Parrish RK 2nd. The cupped disc. Who needs neuroimaging? *Ophthalmology.* 1998;105(10):1866-74.
- Gu S, Glaug N, Cnaan A, Packer RJ, Avery A. Ganglion cell layer-inner plexiform layer thickness and vision loss in young children with optic pathway gliomas. *Invest Ophthalmol Vis Sci.* 2014;55(3):1402-8.
- Herro AM, Lam BL. Retrograde degeneration of retinal ganglion cells in homonymous hemianopsia. *Clin Ophthalmol.* 2015;9:1057-64.
- Iorga RE, Moraru A, Ozturk MR, Costin D. The role of optical coherence tomography in optic neuropathies. *Rom J Ophthalmol.* 2018;62(1):3-14.
- Jaumandreu L, Sánchez-Gutiérrez V, Muñoz-Negrete FJ, de Juan V, Rebolleda G. Reduced Peripapillary and Macular Vessel Density in Unilateral Postgeniculate Lesions with Retrograde Transsynaptic Degeneration. *J Neuroophthalmol.* 2019;39(4):462-9.

Lee IH, Miller NR, Zan E, Tavares F, Blitz AM, Sung H, et al. Visual defects in patients with pituitary adenomas: the myth of bitemporal hemianopsia. *AJR Am J Roentgenol.* 2015;205(5):WS12-8.

Loo JL, Tian J, Miller NR, Subramanian PS. Use of optical coherence tomography in predicting post-treatment visual outcome in anterior visual pathway meningiomas. *Br J Ophthalmol.* 2013;97(11):1455-8.

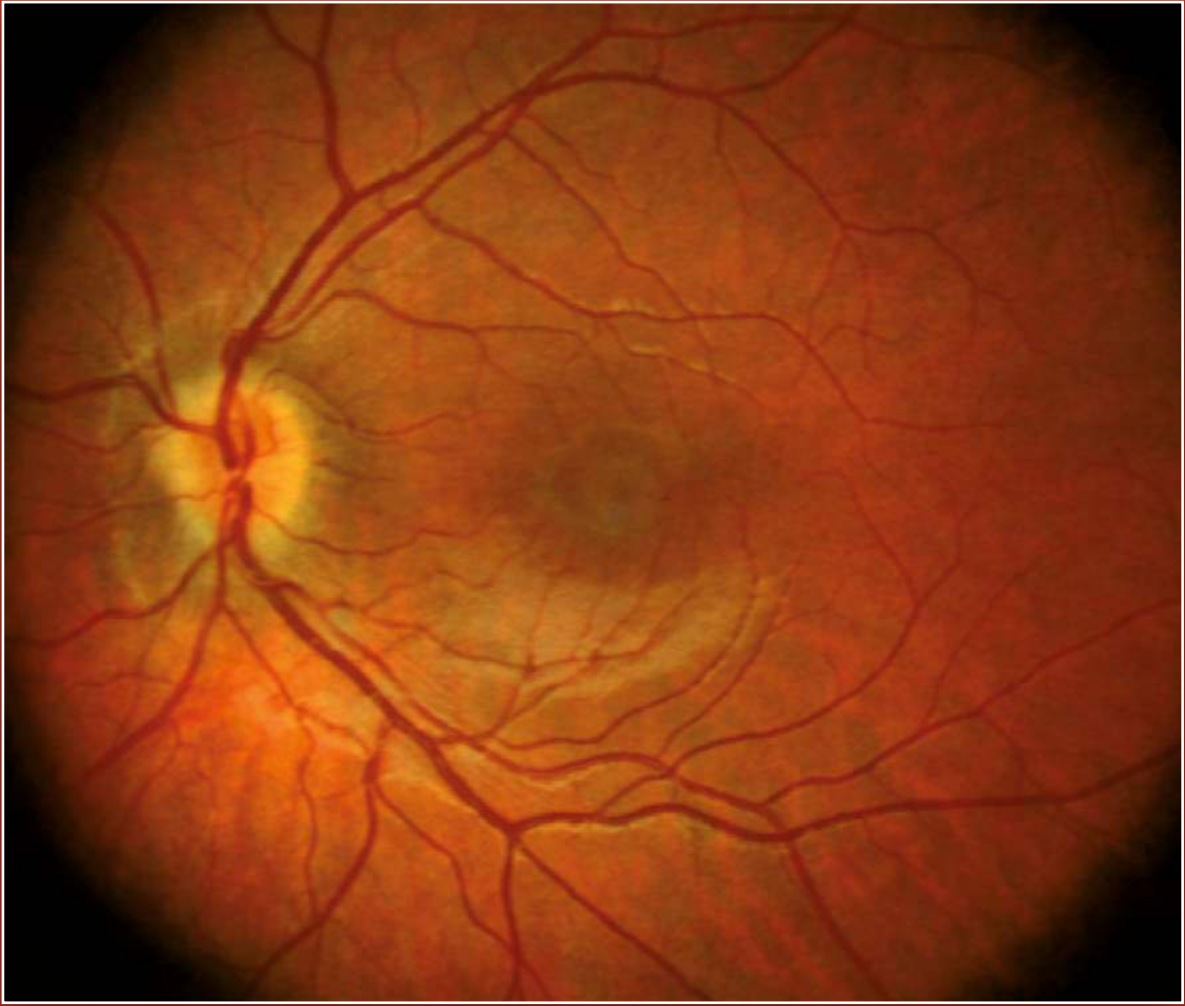McCoy AN, Quigley HA, Wang J, Miller NR, Subramanian PS, Ramulu PY, et al. Development and validation of an improved neurological hemifield test to identify chiasmal and postchiasmal lesions by automated perimetry. *Invest Ophthalmol Vis Sci.* 2014;55(2):1017-23.

Park HY, Park YG, Cho AH, Park CK. Transneuronal retrograde degeneration of the retinal ganglion cells in patients with cerebral infarction. *Ophthalmology.* 2013; 120(6): 1292-9.

Rebolleda G, Díez-Álvarez L, Arrondo E, Ley L, Martínez-San Millán J, Muñoz-Negrete FJ. Neurological Hemifield Test in binasal defects. *Invest Ophthalmol Vis Sci.* 2015;56(4):2568-9.

Rebolleda G, Díez-Álvarez L, Casado A, Sánchez-Sánchez C, De Dompablo E, González-López JJ, et al. OCT: new perspectives in neuro-ophthalmology. *Saudi J Ophthalmol.* 2015;29(1):9-25.

Rebolleda G, Muñoz-Negrete FJ. Protocolos en Neuro-Oftalmología. 86 Congreso de la Sociedad Española de Oftalmología. Madrid: Sociedad Española de Oftalmología; 2010. p. 48-52; 82-119; 123-30.



Acquired Neurological Defects: Toxic and Metabolic

10

Marta Mármol Díaz
María Isabel Canut Jordana
Gema Rebolleda Fernández

A

Definition

Optic neuropathies secondary to toxic neuropathies and nutrient deficiencies present similar clinical features and share etiopathogenesis.

B

Etiopathogenesis and Prevalence

Exposure to toxic agents can occur through voluntary abuse, in work environments or during therapeutic use.

The mechanism of optic neuropathies associated with nutrient deficiencies is more controversial, and it seems that the deficiency really acts as a trigger in the presence of other associated factors (toxic substances or genetic disorders).

As a common final mechanism, an interference occurs in the mitochondrial respiratory chain with more pronounced damage in tissues with the highest energy demand, such as the retinal ganglion cells of the papillomacular bundle.



Classification

a) Nutritional-metabolic optic neuropathy:

- **Vitamin B₁₂ (cobalamin):** The most frequent cause of pernicious anaemia. The associated optic neuropathy can either be accompanied by other neurological disorders or not.
- **Vitamin B₆ (pyridoxine), vitamin B₁ (thiamin), folic acid.** Neuropathies attributed to vitamin B₆ and B₁ deficiencies have been described, although the causal link is not clear. Some pharmaceutical drugs (isoniazid, chloramphenicol, penicillamine) affect the requirements for these vitamins. It is likewise controversial to attribute an optic neuropathy to a deficiency of folic acid, as it is often associated with other nutrient deficiencies.
- **Ethanol:** Chronic alcohol consumption is not considered to be a cause of toxic optic neuropathy, although it is a risk factor as it induces a deficiency of the vitamin B complex.

b) Toxic optic neuropathy:

- **Ethambutol:** This is used to treat tuberculosis and is the most common cause of toxic optic neuropathy. The toxicity depends on the dosage (normally >35 mg/day) and the length of the treatment (exceptionally under two months, with an average onset after seven months). It is estimated that, at above 25 mg/kg-day, the toxicity incidence is 6%. Vision loss is usually reversible if it is detected and the treatment is stopped early (Fig. 1). Vision recovery can be observed several months after the suspension of the treatment. Optical coherence tomography (OCT) can detect changes in the thickness of the peripapillary retinal nerve fibre layer (RNFL) and macular ganglion cells, which could be clinically overlooked.

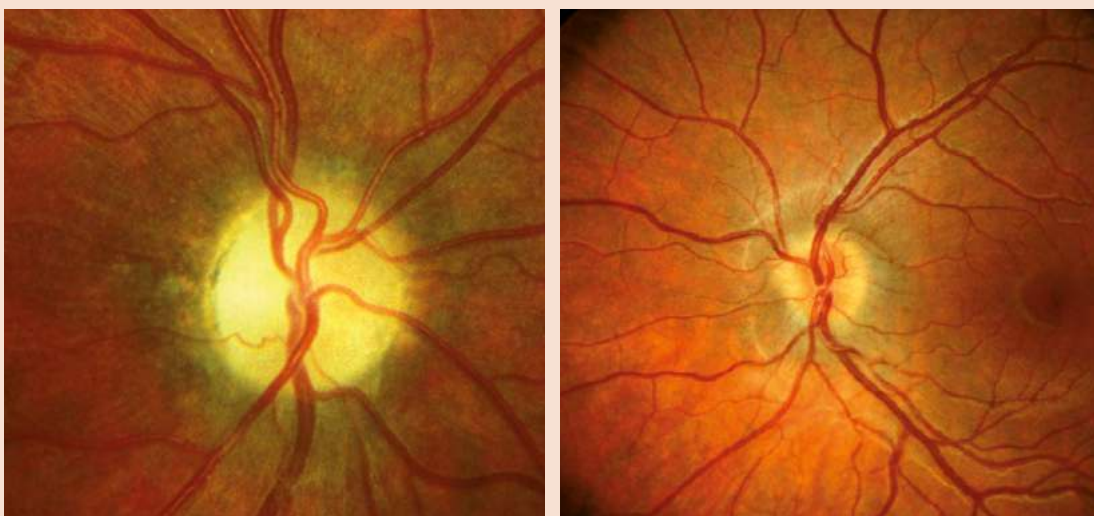


Figure 1. Ethambutol-induced optic neuropathy. Diffuse pallor of the optic disc; usually bilateral.

- **Methanol:** Toxicity caused by methyl alcohol results in severe vision loss, and cases of amaurosis are not rare. Poor pupillary response indicates a bad visual prognosis. At the acute stage, the optic nerve head may appear hyperemic and swollen, rapidly progressing to optic pallor (Fig. 2).

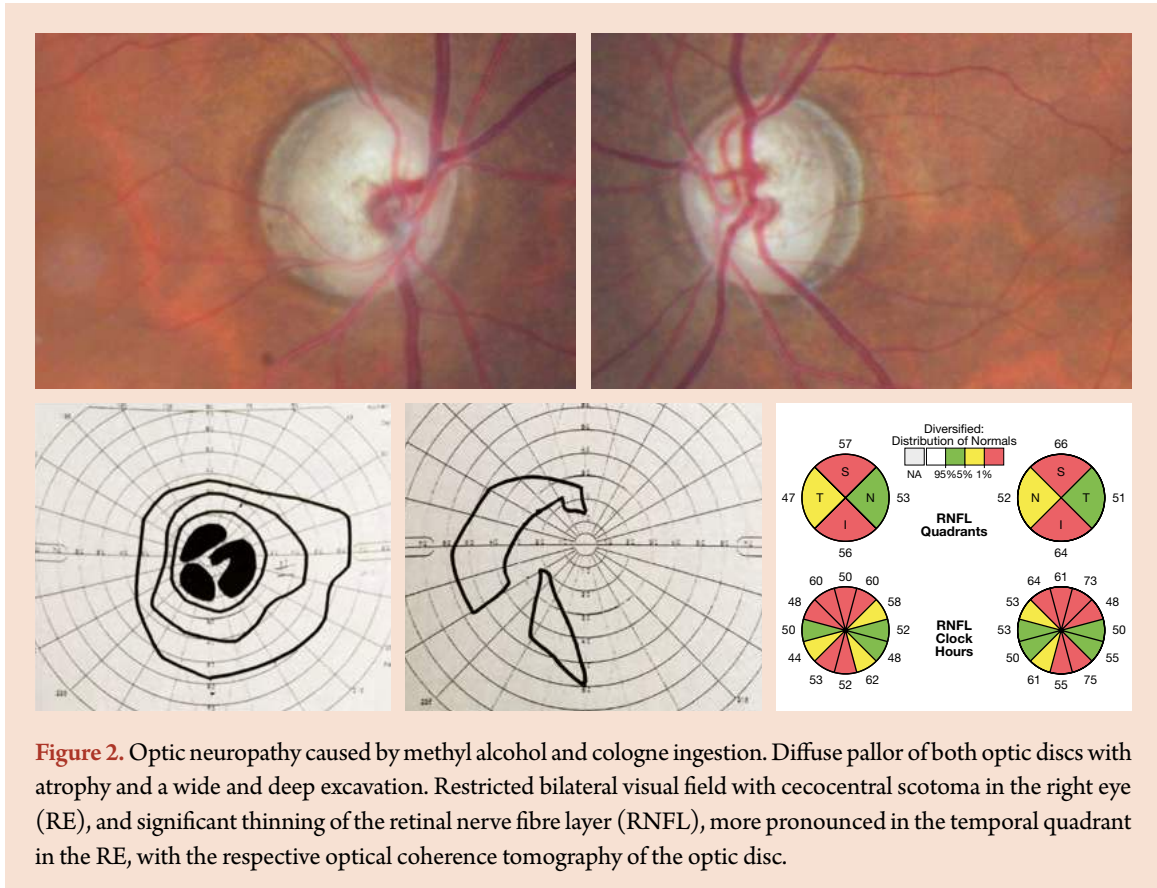
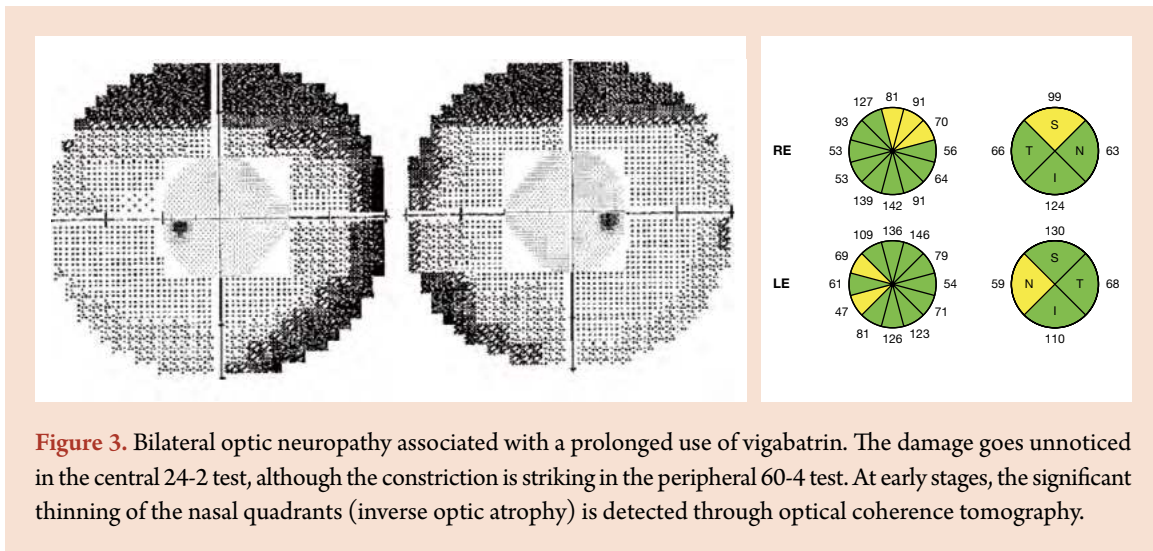


Figure 2. Optic neuropathy caused by methyl alcohol and cologne ingestion. Diffuse pallor of both optic discs with atrophy and a wide and deep excavation. Restricted bilateral visual field with cecocentral scotoma in the right eye (RE), and significant thinning of the retinal nerve fibre layer (RNFL), more pronounced in the temporal quadrant in the RE, with the respective optical coherence tomography of the optic disc.

- **Linezolid:** The use of this antibiotic in multi-resistant infections can cause a usually irreversible peripheral neuropathy, as well as an optic neuropathy that, unlike the peripheral neuropathy, reverses when the therapy stops.
- **Disulfiram:** This is used to treat chronic alcoholism. It is very difficult to distinguish between vision loss due to relapse in the toxic habit and the loss caused by the withdrawal therapy itself.
- **Amiodarone:** The most frequent side effect of this antiarrhythmic medication is cornea verticillata. However, the associated optic neuropathy presents certain particular features that differentiate it from typical ischemic types: insidious onset, bilateral (usually simultaneous) vision loss, slow progression and optic disc oedema that can persist longer than two to three months.
- **Chemotherapy:** Some pharmaceutical drugs (vincristine, cyclosporine A, tacrolimus, 5- fluorouracil) may cause peripheral neuropathy and, less frequently, ptosis, ophthalmoplegia or facial paralysis.
- **Carbon monoxide:** Cases of both cortical blindness and optic neuropathy have been described.

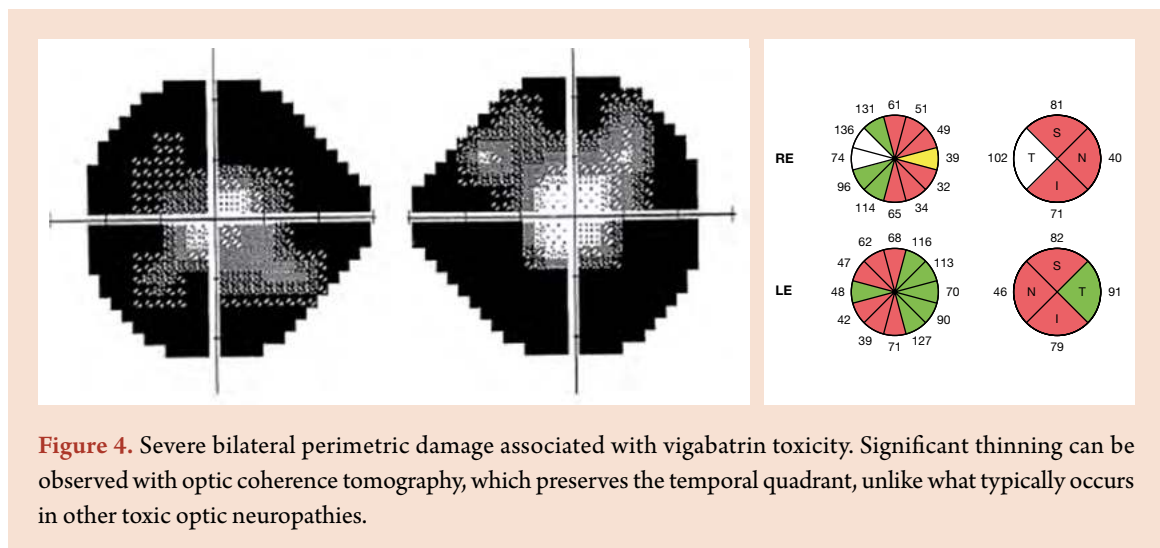
- **Tobacco:** It occurs most frequently after the age of 40, especially in men, and in pipe or cigar smokers. It is considered a diagnosis by exclusion and requires the presence of associated mitochondrial disease (genetic Leber mutations) to be ruled out.
- **Toluene:** This is a widely used organic solvent (used in fuel, paint, coatings, resins, varnishes, adhesives, etc.). Cases of optic neuropathy have been described in people addicted to the inhalation of glue fumes.
- **Vigabatrin:** This medication is used to treat epilepsy. The symptoms mimic glaucomatous optic neuropathy as, unlike the other toxic optic neuropathies, vision is preserved until the final stages, and it causes a peripheral constriction of the bilateral visual field. An early diagnosis requires a peripheral visual field examination (60-4), as the damage may go unnoticed with conventional perimetry (24-2 or 30-2) (Fig. 3). OCT has shown that the damage starts in nasal quadrants, unlike with the other toxic types, which have a predilection for the papillomacular bundle.



D

Clinical Signs

The characteristic clinical picture is painless, bilateral and simultaneous vision loss, although a certain asymmetry can be found in its early stages, with an insidious onset, except in the case of methanol intoxication, which progresses with severe and sudden vision loss. At the beginning, the optic nerve head usually has a normal appearance, except in the case of methanol-associated oedema, and it progressively develops to disc pallor, which usually predominates in the temporal quadrant, except in the case of vigabatrin (Figs. 3 and 4).



As regards visual fields, the characteristic defects are central or cecentral scotoma. The OCT shows that the thinning of the RNFL is symmetrical and predominates in the temporal quadrants, except in cases of toxicity associated with vigabatrin (inverse optic atrophy).

E

Differential Diagnosis

- Optic neuropathies of inflammatory/demyelinating, ischemic, compressive origin.
- Maculopathies.
- Hereditary degenerative optic atrophies (dominant optic atrophy and Leber hereditary optic neuropathy).

F

Ocular and Systemic Associations

Systemic:

- Nutritional deficiencies.
- Genetic diseases (especially mitochondrial genetic diseases).
- Exposure to toxic agents.

G

Key Points

1

Toxic or Nutritional neuropathies are diagnosed by exclusion. Toxic history and characteristic clinical features are required:

- Evidence of exposure to toxic agents or dietary anomalies.
- Painless, bilateral, symmetrical and slowly progressing decrease in visual acuity (except in the case of methanol).
- Dyschromatopsia and central or cecocentral scotoma.
- Optic nerve head initially normal in appearance (except in the case of methanol).

2

Perimetry, a colour test and OCT are necessary for early diagnosis.

3

At the optic atrophy stage, OCT shows bilateral and symmetrical thinning that predominates in the temporal quadrant, except in cases associated with vigabatrin (Fig. 4).

4

Since they are diagnosed by exclusion, in many cases it is necessary to include neuroimaging to rule out other reasons for the optic neuropathy.



Bibliography

- Altiparmak UE. Toxic optic neuropathies. *Curr Opin Ophthalmol*. 2013;24(6):534-9.
- Attarchi MS, Labbafinejad Y, Mohammadi S. Occupational exposure to different levels of mixed organic solvents and colour vision impairment. *Neurotoxicol Teratol*. 2010;32(5):558-62.
- Betancur-Sánchez AM, Vásquez-Trespacios EM, Sardi-Correa C. Impaired colour vision in workers exposed to organic solvents: a systematic review. *Arch Soc Esp Oftalmol*. 2017;92(1):12-8.
- Contreras I, Rebolleda G, Noval S, Muñoz-Negrete FJ. Optic disc evaluation by optical coherence tomography in nonarteritic anterior ischemic optic neuropathy. *Invest Ophthalmol Vis Sci*. 2007;48(9):4087-92.
- Elder M, Rahman AM, McLay J. Early paracentral visual field loss in patients taking hydroxychloroquine. *Arch Ophthalmol*. 2006;124(12):1729-33.
- Grzybowski A, Zülsdorff M, Wilhelm H, Tonagel F. Toxic optic neuropathies: an updated review. *Acta Ophthalmol*. 2015;93(5):402-10.
- Kardon RH. Role of the macular optical coherence tomography scan in neuro-ophthalmology. *J Neuroophthalmol*. 2011;31(4):353-61.
- Kjellstrom U, Andréasson S, Ponjavic V. Attenuation of the retinal nerve fibre layer and reduced retinal function assessed by optical coherence tomography and full-field electroretinography in patients exposed to vigabatrin medication. *Acta Ophthalmol*. 2014;92(2):149-57.
- Mendel T, Fleischman D, Allingham RR, Tseng H, Chesnutt DA. Spectrum and clinical course of visual field abnormalities in ethambutol toxicity. *Neuroophthalmology*. 2016;40(3):139-45.
- Meyer-Baron M, Blaskewicz M, Henke H, Knapp G, Muttray A, Schaper M, et al. The impact of solvent mixtures on neurobehavioral performance: conclusions from epidemiological data. *Neurotoxicology*. 2008;29(3):349-60.
- Rebolleda G, Díez-Álvarez L, Casado A, Sánchez-Sánchez C, De Dompablo E, González-López JJ, et al. OCT: new perspectives in neuro-ophthalmology. *Saudi J Ophthalmol*. 2015;29(1):9-25.
- Rebolleda G, García Pérez JL, Muñoz Negrete FJ, Tang RA. Vigabatrin toxicity in children. *Ophthalmology*. 2005;112(7):1322-3.
- Rebolleda G, Muñoz-Negrete FJ. Protocolos en Neuro-Oftalmología. 86 Congreso de la Sociedad Española de Oftalmología. Madrid: Sociedad Española de Oftalmología; 2010. p. 101-6.
- Rebolleda G, Muñoz-Negrete FJ, Gutiérrez C. Screening of patients taking vigabatrin. *Ophthalmology*. 2000;107(7):1219-20.

Collection Librairie Médicale Théa

editorialglosa



12 Rue Louis Blériot - ZI du Brézet
63017 Clermont-Ferrand cedex 2 - France
Tel. +33 (0)4 73 98 14 36 - Fax +33 (0)4 73 98 14 38
www.laboratoires-thea.com